

From: Gerald Mayfield, MD
Subject: Re: Mal-rotation union
To: Charles King, CP
Date: Tuesday, January 23, 2007

In the normal, non mal-united femur the greater trochanter is most lateral in relationship with the center of axis of rotation of the hip, providing the attached gluteus medius muscle to be in the most advantageous position due to the maximum lever arm relationship to the center of rotation of the hip. In a typical mal-rotation union of a fracture of the femoral shaft especially those treated in traction, as was the case of many of the [Vietnam] casualties, the distal portion of the fracture along with the knee, leg, and foot are kept in relative internal rotation, (the foot pointed straight up as maintained in balanced traction) while the proximal femoral fx. fragment is externally rotated by the hip external rotator: Thus, the greater trochanter is in relative external rotation and posterior when union occurs.

As the patient ambulates and walks with the foot in normal gait pattern, the proximal femur including the greater trochanter is posterior and therefore the maximum lever arm to the center of rotation of the hip has been shortened. This is what our x-ray studies showed as measurements were done from a point on the greater trochanter to the center of rotation of the hip. Thus, the abductors of the hip are at a disadvantage and a "gluteus medius weakness" type of limp develops. This held true for our patients with mal-rotation and as I recall the limp could be somewhat decreased by walking with the foot in an exaggerated internal rotation position, positioning the greater trochanter laterally and the G. medius in more optimum position.

From: Gerald Mayfield, MD
Subject: Re: Hip rotation
To: Charles King, CP
Date: Sunday, September 30, 2007

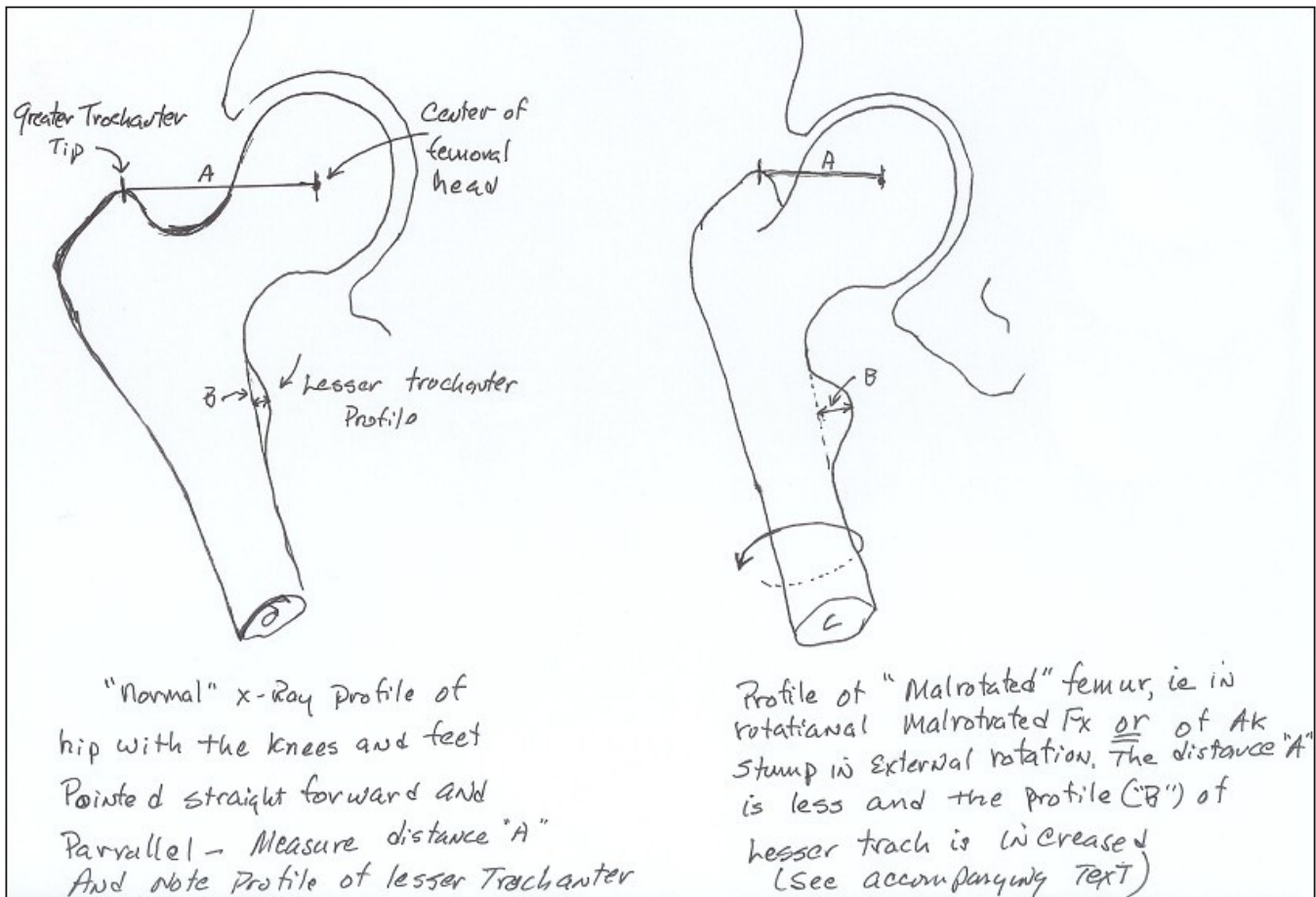
Attached is a rough diagram of the method of determining hip rotation I came up with in studying rotational mal-union of the femur . . . I think it does have significant ramifications as to the amount of "gluteus medius weakness" limp in the amputee gait. The [Vietnam] patients with femoral mal-rotation union that were treated in traction with the foot maintained straight up, all had that typical gait.

I will try and be as brief as possible as to the biomechanics involved here. When a person stands "one legged" over a normal lower extremity with their body weight all applied to that extremity through the hip joint, as in the stance phase of walking, a lever arm mechanical system is produced with the hip abductor muscles stabilizing the pelvis, trunk and entire body over that hip by exerting a force to the attachment at the greater trochanter that is then equalized by the counter force in the hip joint. (illustrated by the 200# vector forces in diagram #2 [Page 3]) This is a basic Force X Distance relationship with the distance being illustrated by "A" in both diagrams and the forces by the vector lines.

In the "normal" hip/extremity diagram this distance of "A" is, arbitrarily on this drawing, 1.5". When this "normal" relationship exists and "equilibrium" exists from the balanced muscle/hip joint forces the trunk/upper body does not have to shift over the affected hip to maintain balance.

When a "mal-rotation" condition exists either from fx mal-union OR external rotation of the hip in an AK stump caused by the un-resisted pull of the iliopsoas muscle which attaches to the lesser trochanter and the short hip external rotators that are attached just distal to the greater trochanter and externally rotate the hip. The gluteus maximus muscle which is posterior and also the posterior part of the gluteus medius muscle are also external rotators. In summary they basically overpower the only internal rotator muscle left proximal is the anterior portion of the gluteus medius. The rest of the hip internal rotators apply their forces more distally along the femur to the knee and are not as effective in a mal-union or don't apply force at all in an AK amputee.

Back to the measurement of x-rays: In the mal-rotated state (#2 in the second diagram [Page 3]) the greater trochanter and attached gluteus medius muscle goes posterior decreasing the distance of the lever arm "A" and diminishing the equalizing force in the FxD relationship and the body compensates by shifting the trunk over to a more "centered" position over the hip joint, i.e. the "GM limp" An objective measurement made of the distance "A" can be made, i.e. shortened in external rotation.



The lesser trochanter normally does not have much of a profile on the normal x-ray, however when the proximal femur goes into external rotation it moves from its more posterior (hidden) position to become quite prominent, a sign external rotation is present and perhaps even this change in profile distance could be measured. I initially did these calculations on x-rays of a skeletal femur and hip joint to calibrate just how much rotation coincided with the "A" measurement.

Well I have become quite long winded in getting wound up in the biomechanics when you asked just for how measurements were made. Hopefully it makes some sense. . . I will attach two diagrams to two different e-mails, to this one will be the drawing without vector lines [page 2 above] and diagram #2 [below] in a subsequent e-mail with vector lines drawn [also sent 09/30/07].

Sincerely,

Jimmy Mayhew

