



# Newsletter



## Prosthetics and Orthotics Clinic

Vol. 4, No. 3/1980

Autumn (Issued Quarterly)

We apologize for the delay in the publication of the Newsletter which was a result of the disruption caused by the move of the National Office and the complete changeover of the personnel in the Publications Office.

## Irreversible Contractures: An Impediment to Prosthetic Rehabilitation

Justin Alexander, Ph.D.<sup>1</sup>

Prosthetic rehabilitation of patients with severe contractures of the remaining joints of the affected lower extremity has been generally viewed as being difficult due to biomechanical problems in fitting, increased energy costs of ambulation and poor cosmesis of the prosthesis. As a result, attempts are often made to "stretch out the contracture" with minimal success, or suggestions are made to the patient to remain in the wheelchair. Our experiences with a number of patients who presented with "irreversible" contractures, indicate that another choice may be available.

In 1965(1) we reported our experience in the management of a 59 year old man who had undergone bilateral amputations (BK and AK). Following a herniorrhaphy, he developed occlusions of both iliac arteries and despite attempts to reconstruct the vascular supply, he developed gangrene necessitating the amputations. When he was examined by us, he presented with bilateral hip flexion contractures of about 60° and a knee flexion contracture on the BK side of 90°. In addition, there was limited mobility of the lumbar spine. Primarily because the patient refused our recommendation for wheelchair independence, pylons were constructed. For the left, a bent knee pylon was fabricated and for the right the device was built to hold the stump in about 50° hip flexion with weight bearing on the posterior thigh. Since the patient demonstrated that this solution was a realistic one, prosthetic devices incorporating the features of the pylons were made. When the patient was discharged, he was able to ambulate with the aid of Lofstrand crutches.

The patient was re-examined periodically, and *after about 2 years* it was noted that the contractures had decreased to a point where he was able to wear a PTB prosthesis on the left and a conventionally aligned AK quadrilateral socket prosthesis on the right.

Lippman(2) described his observations of a 72 year old man who lost his right leg as a result of trauma, complicated by a long history of arteriosclerosis obliterans. Because of a 40° hip flexion contracture, his prosthetic treatment followed the course outlined above.

In our prosthetics clinic (Bronx Municipal Hospital Center), we have seen a number of patients who had undergone below knee amputations and presented with severe knee flexion-hip flexion contractures to a degree which precluded fitting with a standard PTB or condylar bearing prosthesis. We have frequently fitted them with bent knee pylons followed by a similar prosthetic device after they had demonstrated their ability to function with the temporary device. On follow-up we again noted reduction of the "irreversible" contractures to the point where a more conventionally aligned prosthesis could be prescribed.

### Discussion

Delagi and co-workers(3) (1955) as well as Blau, *et. al*(4) (1951) reported their impressions of the benefits of ambulation with a temporary device. Both emphasized the stretching effect of early ambulation. In the devices described in this article, however, stretching has been purposely minimized because the contractures were believed to be "irreversible." Despite the lack of

active stretching, the contractures were relieved to a considerable degree.

Partridge and Duthie (1963)(5) reviewed the literature describing the effect of immobilization on acutely inflamed rheumatoid joints and cite Hunter (1835) "nothing can promote contraction(s) of a joint so much as motion before the disease is removed." Hunter's observations were confirmed by Thomas (1878), Duthie (1951, 1952) and Partridge and Duthie. Harris and Copp(6) (1962) immobilized acutely inflamed knee joints, keeping one completely immobilized and the other being exercised intermittently. They noted that when the fixed knee lost more than 15° of motion, the mobile knee also lost range, thereby suggesting that some factors other than immobility might be a contributing factor. In their opinion immobilization produced a decrease in muscle spasm, thus permitting restoration of motion.

Fried (1969)(7) concurs "complete immobilization is not only *not* harmful but frequently beneficial, provided that splinting is done judiciously, especially when a joint is inflamed and painful." Under those conditions when patients are likely to dread motion, immobilization leads to decreased pain and inflammation and "it is not unusual for immobilization to result in increase in motion."

It seems that those amputees who experience considerable pain pre-operatively or in the immediate post-operative period, might react with a response similar to that described above and when pain is relieved, inhibition, spasm or another mechanism is decreased and motion can be restored.

In addition, it appears that the judgment of "irreversible contractures" may be applied too quickly. Patients are treated for a finite period of time and if during that period no appreciable change is observed, a decision must be made based on demonstrable facts.

It can, therefore, be concluded that for some patients

interim solutions as outlined may be appropriate and that the clinic staff must accept the responsibility for regular, periodic and long term follow-up of patients in order to facilitate accommodation to changes in the patient's condition.

#### References

1. Alexander, Justin and Herbison, Gerald, "Prosthetic Rehabilitation of a Patient With Bilateral Hip-Flexion Contractures: Report of a Case." *Archives of Physical Medicine and Rehabilitation*, Vol. 46, 708-711, October, 1965.
2. Lippmann, Heinz I., "Rehabilitation of the Lower Extremity Amputee with Marked Flexion Contractures: Report of Two Cases." *Archives of Physical Medicine and Rehabilitation*, Vol. 48:3, 147-149, March, 1967.
3. Delagi, Edward F., Abramson, Arthur S. and Tauber, Arthur N., "Use of Temporary Plaster Pylon in the Management of the Lower Extremity Amputee." *Archives of Physical Medicine and Rehabilitation*, Vol. 36: 784-786, December, 1955.
4. Blau, Leslie, Phillips, Joseph J. and Rose, Donald M., "Value of the Pylon in Pre-prosthetic Management of the Lower Extremity Amputee." *Archives of Physical Medicine and Rehabilitation*, Vol. 32: 585-589, 1951.
5. Partridge, R. E. H. and Duthie, J. J. R., "Controlled Trial of the Effect of Complete Immobilization of the Joints in Rheumatoid Arthritis." *Ann. Rheum. Dis.*, 22: 91, 1963.
6. Harris, R. and Copp, E. P., "Immobilization of the Knee Joint in Rheumatoid Arthritis." *Ann. Rheum. Dis.*, 21: 353, 1962.
7. Fried, David M., "Splints for Arthritis." *Arthritis and Physical Medicine*, S. Licht (edit.), 1969, pp 285-314.

## Meetings and Seminars

1981, January 27-February 1, AAOP Round Up Seminar, Fontainebleau Hilton, Miami, Florida.

1981, April 23-25, Region IV Annual Meeting, Hyatt Regency, Lexington, Kentucky.

1981, June 5-7, AOPA Region IX and the California Orthotics and Prosthetics Combined Annual Meeting, Doubletree Inn, Monterey, California.

1981, June 12-14, AOPA Region II and III Meeting, Host Farms, Pennsylvania.

1981, June 16-21, AOPA Regions VII, VIII, X, XI Combined Meeting, Four Seasons Motor Inn, Colorado Springs, Colorado.

1981, June 25-27, AOPA Region VI and Midwest Chapter of AAOP Annual Meeting, at the Holiday Inn of Merrillville, Indiana.

1981, October 27-November 1, AOPA National Assembly, Sahara Hotel, Las Vegas, Nevada.

1982, May 6-9, Region IV Meeting, Radisson Plaza Hotel, Nashville, Tennessee.

1982, May 13-16, Region II and III Meeting, Caesar's World, Atlantic City, N.J.

1982, April 29-May 2, AOPA Regions VII and VIII, Combined Meeting, Alamada Plaza, Kansas City (Tentative).



# Questionnaire

Since the scope of the *Newsletter, Prosthetics and Orthotics Clinic* has been expanded, we would appreciate your reaction to a possible change of title:

1. Keep as is
2. Digest of Prosthetics and Orthotics Clinics
3. Orthotics and Prosthetics Clinics
4. Orthotics and Prosthetics Digest
5. Other: \_\_\_\_\_

## An Ankle-Foot Orthosis Providing Mediolateral Stabilization While Allowing Free Plantar and Dorsiflexion of the Foot

Lucia Klemmt, C.O.  
Fritz Klemmt

The development of an ankle-foot orthosis (AFO) providing mediolateral stabilization while allowing free plantar and dorsiflexion of the foot was prompted by a patient (W. F.) seen some months ago, who was wearing a posterior solid ankle-foot orthosis (PSAFO). However, rather than providing ankle stability, it was ineffective and an irritant during stance. W. F. was unhappy with it, and discouraged.

In evaluating his condition, he was found to have good plantar and dorsiflexion, but suffered from mediolateral ankle instability. He was shown a conventional AFO with a metal stirrup and metal uprights, demonstrating the mediolateral protection the orthosis provides, while allowing free motion at the ankle. The fact that it was less cosmetic than a plastic orthosis did not concern the patient, if it allowed him to walk normally again and not with a stiff ankle. But considering his physician's preference for plastic over a metal orthosis, with its advantages, e.g., free choice of shoes, better appearance, etc., it occurred to us to combine mediolateral protection of the ankle with free ankle flexion-extension in a plastic orthosis.

This idea was realized by incorporating an ankle joint similar to that used in fracture bracing in a PSAFO (Figure 1). From a plaster mold of the patient's limb, a PSAFO was fabricated with an anterior section for added tibial support. The distal aspect of the calf section was trimmed to clear the Achilles tendon. The proximal edge of the footplate was trimmed so as to include the malleoli (Figure 2). A contoured bar was

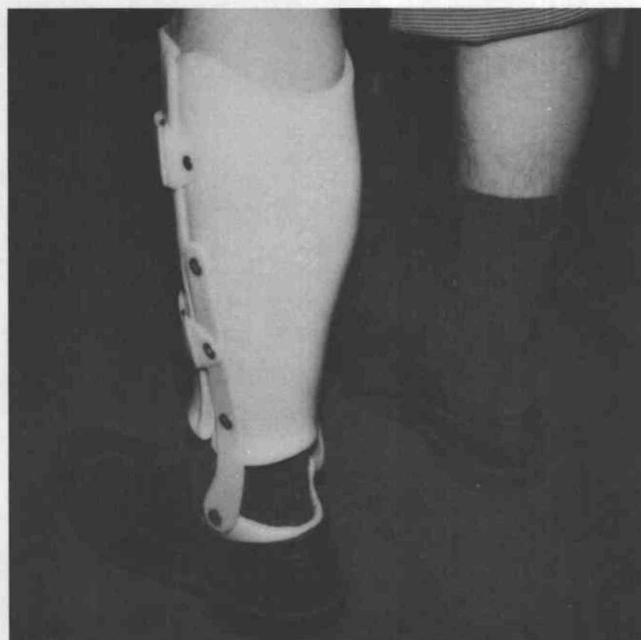

Figure 1

riveted to the lateral aspect of the posterior calf portion and joined with the footplate over the malleoli, creating a pivot point allowing rotation necessary for flexion or extension (Figure 3). Two velcro straps pro-

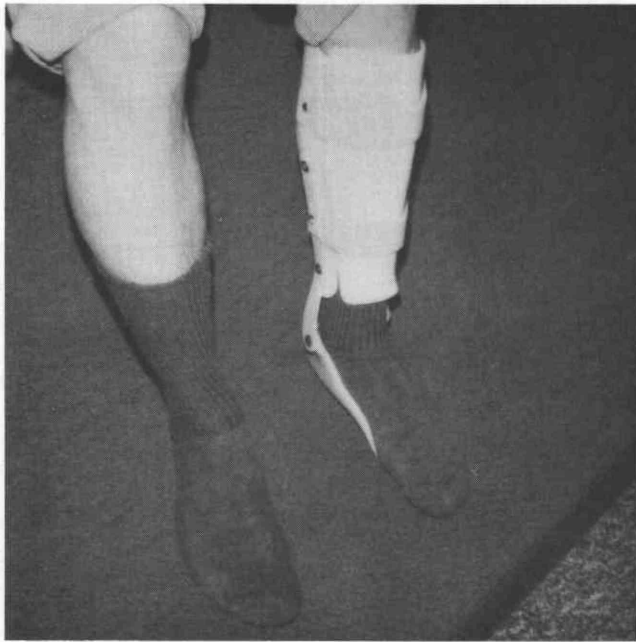

Figure 2

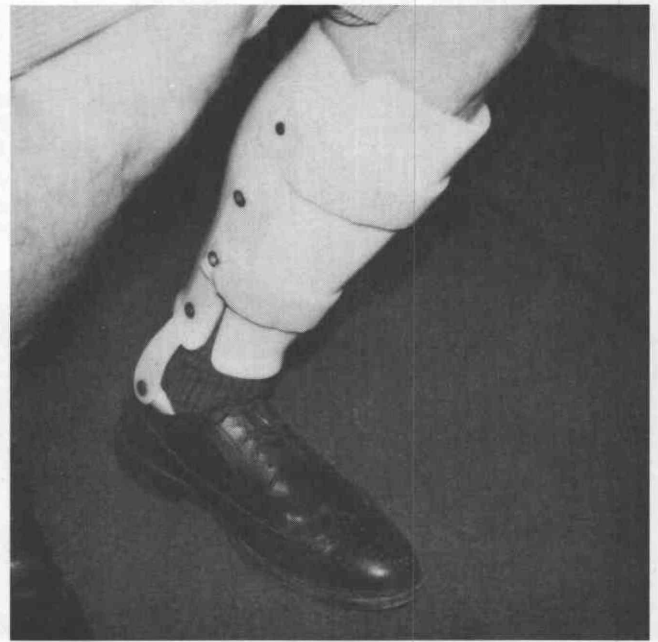

Figure 3

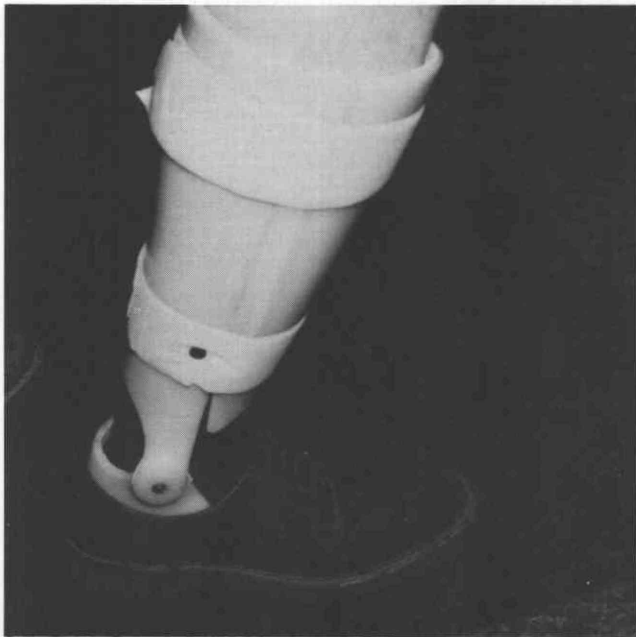


Figure 4a

vided an intimate fit around the limb. The patient was pleased with the function and support provided by this orthosis.

The second patient fitted with this type of orthosis (R. R.) had a similar ankle problem. A slight change in the design was made. A separate ankle joint as with W. F.'s orthosis was not used. Rather, the proximal edges of the footplate were extended to the proximal aspect of the malleoli. The distal edges of the posterior calf section were then made to overlap the malleoli portions of the foot plate (Figures 4a and 4b). This joint system works smoothly and is more cosmetic, although it requires a little more work. R. R. was delighted with the orthosis since he can wear it with regular Oxfords or boots (Figures 5 and 6).

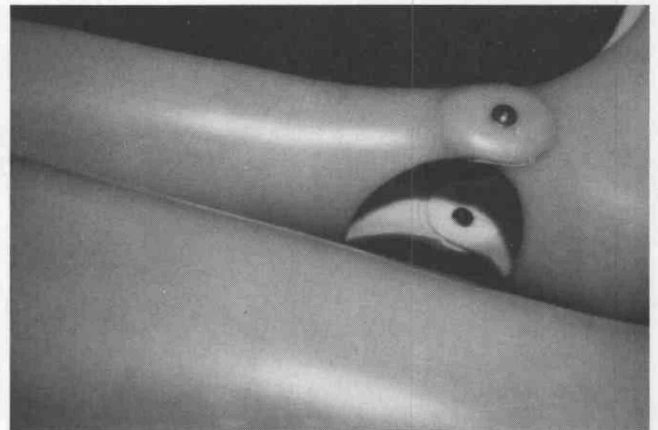

Figure 4b

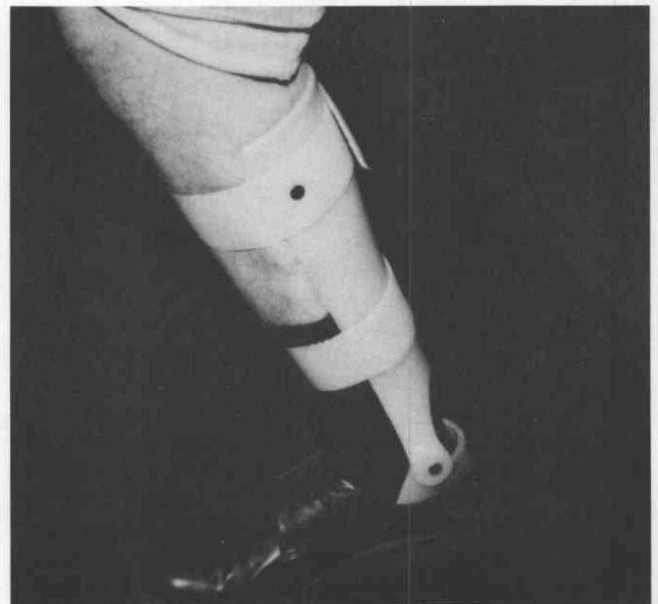

Figure 5

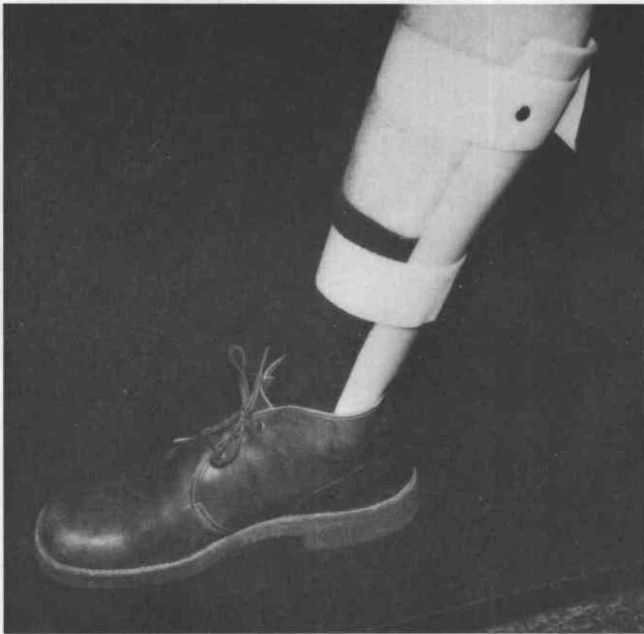


Figure 6

A third patient (P. B.) with a similar problem of ankle instability was fitted with the same type of orthosis made for R. R., but eliminating the anterior portion. This patient, too, was happy with the freedom of motion it allowed (Figure 7).

In these three cases, free plantar and dorsiflexion were allowed while mediolateral ankle stability was

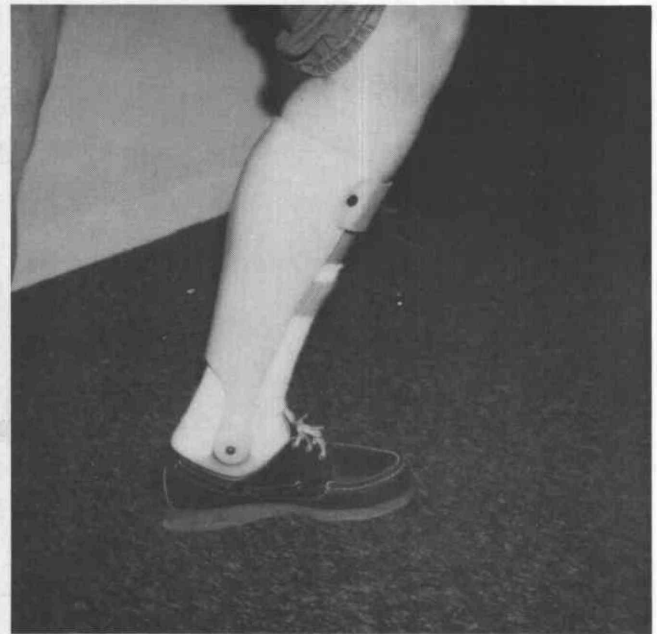

Figure 7

achieved. Though it involves extra work and time during fabrication of this type of ankle joint on a posterior solid ankle foot orthosis, the security of the ankle on weight bearing, the freedom of movement while walking, and the satisfaction of the patients wearing the orthosis are achievements justifying the extra effort and expense.

## *An Editorial*

# The Driving Force in Rehabilitation

William M. Susman, M.A., R.P.T.<sup>1</sup>

By design, and in daily clinical practice, rehabilitation is a multi-disciplinary effort. The patient is best served by professionals addressing the psychosocial and vocational aspects of disability as well as the various aspects of physical impairment in a specialized manner. The driving force behind the effective functioning of this approach is communication among the professionals comprising the rehabilitation team. This communication may occur within the structured format

of professional publications, the formal yet often spontaneous settings of team clinics and rounds, or the many informal daily contacts between colleagues involved in the treatment of any one patient.

Such communication enhances patient management in numerous ways. Consistent definitions and coordination of treatment approaches and goals can be achieved. Different perspectives regarding the same clinical situation can be shared, perspectives tempered by

the different relationship each team member has with the patient, the expertise each member brings to the clinical problem, and the priority of concerns each establishes according to his or her functional role. Perhaps most importantly, the team is able to bring its collective clinical experience to bear upon the problem at hand. No one clinician, regardless of depth or breadth of experience, should fail to search out and use this collective experience for it can only serve to

broaden the range of possible solutions.

An excellent example of such an opportunity is provided in the lead article by Dr. Alexander in this issue of the Newsletter. This is not to say that executive decisions should not be made in the rehabilitation setting, but that if they are based upon the communicated experience and viewpoints of all team members, such decisions will not be autocratic.

It should not be forgotten that the clinician also benefits from such communication. The most stimulating workplace is one in which a free exchange of ideas can take place without the fear that

image or role is being threatened. In an imperfect world with personality differences and professional pressures, this can be hard to achieve, but must be actively sought. The stimulation of thought through this collective process also leads to clinical innovation and new research ideas and, ultimately, improvement in the professional's level of expertise and advancement of the state of the art of rehabilitation as a whole.


Clinical professions involved in rehabilitation are currently undergoing rapid growth in knowledge base, upgrading of standards for entry into practice, and increasing professional responsibility. The fields of orthotics and prosthetics

and physical therapy may be the best examples of these trends. It is imperative that no one clinical field, regardless of increased training, authority, or specialization becomes more isolated in clinical practice. Obviously, a given level of clinical skill cannot be replaced by input from another discipline, but the effective use of that skill can be channeled by communication within the clinic team towards better patient treatment, our foremost concern.

1. Assistant Professor, Ithaca College, Division of Physical Therapy, Albert Einstein College of Medicine, Jacobi Hospital, Bronx, New York.

# AAOP Round Up Seminar

Fontainebleau Hilton, Miami, Florida  
January 27 — February 1, 1981



*For more information contact:*  
AAOP National Office,  
717 Pendleton St.  
Alexandria, Va. 22314

Summary of Responses to the Questionnaire Appearing in the Spring  
Newsletter, Prosthetics and Orthotics Clinic, Vol. 4, No. 1, 1980

**Prosthetic Suspension Systems**

**1. Below-Knee**

a. P.T.B. supracondylar cuff	35
b. P.T.B. supracondylar cuff with waist belt	20
c. P.T.B. supracondylar cuff with waist belt and fork strap	1
d. P.T.B. with thigh corset	4
e. P.T.B. with thigh corset and waist belt	1
f. P.T.B. with thigh corset, waist belt, and fork strap	5
g. P.T.B. with medial wedge	0
h. P.T.B. with removable medial wall	6
i. P.T.B., supracondylar-suprapatellar	23
j. Conventional BK (open end) with corset	0
k. Conventional BK (open end) with corset and waist belt	0
l. Conventional BK (open end) with corset, waist belt and fork strap	2
m. Other (please list):	3*

Total: 100 %

**2. Above-Knee**

a. Total contact, suction socket	20
b. Total contact, suction socket with Silesian belt	7
c. Open-end suction socket	1
d. Open-end suction socket with Silesian belt	1
e. Total contact with hip joint and pelvic belt	24
f. Total contact, semi-suction, with hip joint and pelvic belt	23
g. Total contact, semi-suction, with Silesian belt	16
h. Open-end, semi-suction, with Silesian belt	0
i. Other (please list):	8**

Total: 100 %

\*PTS with joint and thigh corset, Symes medial opening.

\*\*Leather or plastic adjustable socket, shoulder suspension.

# NEWSLETTER . . . Prosthetics and Orthotics Clinic

A quarterly publication providing the means for interdisciplinary discussion among physicians, therapists, and practitioners. Its eight pages contain important articles, spirited dialogue, and a sense of shared discovery, making it a valuable publication.

Enclosed is my check for \$8.00 for a 1-year subscription to the Newsletter, Prosthetics and Orthotics Clinic. (Foreign Subscription Price is \$9.00.)

**Mail to:**

AAOP  
717 Pendleton St.  
Alexandria, Va. 22314

**Name** \_\_\_\_\_

**Address** \_\_\_\_\_

**City** \_\_\_\_\_

**State** \_\_\_\_\_

**Zip** \_\_\_\_\_

## Newsletter . . . Prosthetics and Orthotics Clinic

American Academy of Orthotists and Prosthetists  
717 Pendleton St., Alexandria, Va. 22314

SECOND CLASS  
POSTAGE PAID AT  
WASHINGTON, D.C.

ADDRESS CORRECTION REQUESTED

\_\_\_\_\_  
\_\_\_\_\_  
\_\_\_\_\_

ACAD19123SAUR H605 S CO  
MR HENRY SAUR  
605 SPRING CRAVDEN ST  
PHILADELPHIA PA 19123

## The American Academy of Orthotists and Prosthetists

### Officers

**President:** Edward Van Hanswyk, C.O.  
*Syracuse, New York*

**President Elect:** Robert F. Hayes, C.P.  
*West Springfield, Massachusetts*

**Vice President:** Richard Lehneis, C.P.O.  
*New York, New York*

**Secretary-Treasurer:** Richard La Torre, C.P.  
*Schenectady, New York*

**Immediate-Past  
President:**

Michael Quigley, C.P.O.  
*River Forest, Illinois*

### Directors

Gunter Gehl, C.P.  
*Chicago, Illinois*

Hugh Panton, C.P.O.  
*Orlando, Florida*

Wade Barghausen, C.P.O.  
*Columbus, Ohio*

Charles Dankmeyer, Jr., C.P.O.  
*Baltimore, Maryland*

### Executive Director

William L. McCulloch  
*Washington, D.C.*