

# APPLICATION OF THE HALO

By VERNON L. NICKEL, M.D., Chief of Surgical Services and Head Orthopedist; JACQUELIN PERRY, M.D., Orthopedist; ALICE GARRETT, M.D., Orthopedist; ROY SNELSON, C.O., Chief Orthotist, Rancho Los Amigos Hospital, Inc., Downey, California

## Introduction

Controlled positioning of the upper thoracic spine, cervical spine and the head has been inadequate with the use of plaster alone. Vertical alignment and more effective immobilization can be obtained with a traction apparatus between the head and body cast such as Crutchfield tongs (1) or Hoen wires (2) which we used on two cases, but separate positioning of the head and cervical or thoracic spine is not possible. This latter control is particularly important in combined cervical and bulbar palsies and high cervical fracture dislocations, and can be obtained by use of the halo traction apparatus. A detailed description of the halo has been previously given (3).

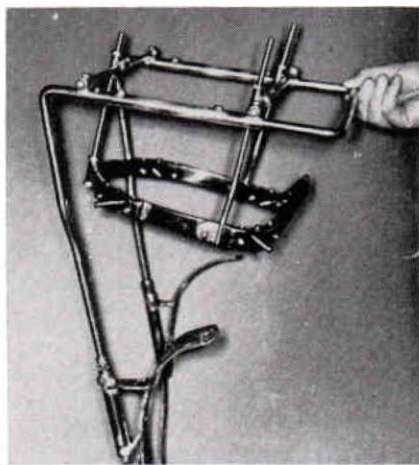


Figure 1

Modification of Dr. F. A. Bloom's apparatus for facio-maxillary traction (4) has given us this essential head control. In order to meet strength requirements the three-quarters reinforced aluminum ring was changed to a complete circle of stainless steel. His method of fastening the apparatus to the head with four broad-shouldered screws has been preserved. Because of its attachment to a cast, the additional weight is not a factor.

The halo consists of the following parts: (See Fig. I and II)

1. Head ring
2. Mounting brackets
3. Overhead support
4. Suspension assembly
5. Halo Skull Pin

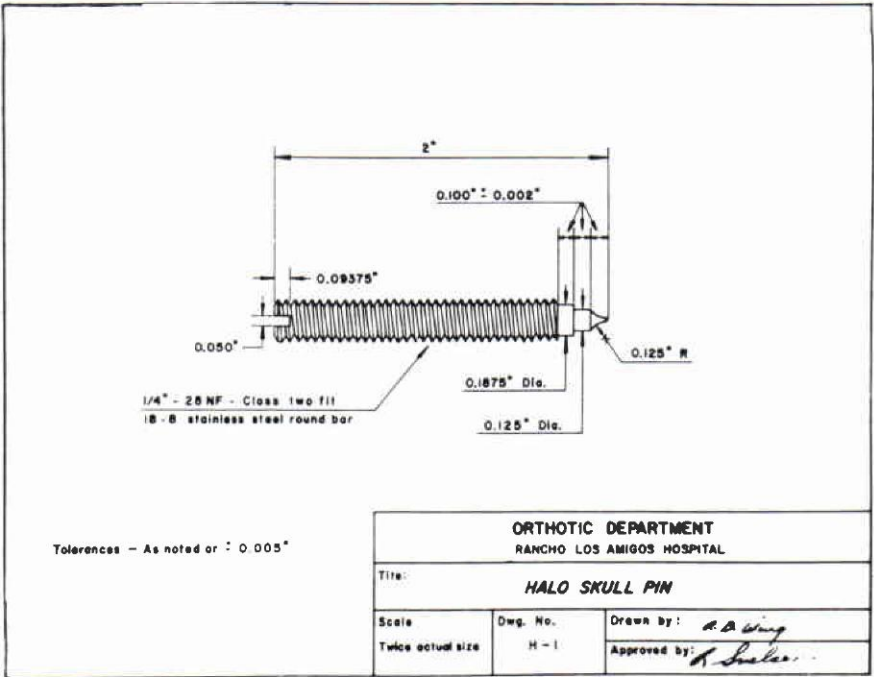
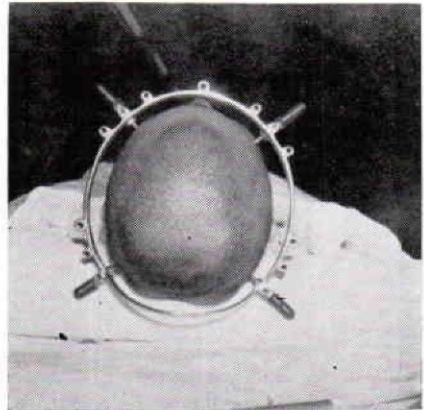


Figure II. Halo Skull Pin.

Figure IV.



The halo ring is applied to the patient's head by the physician. Caution should be taken to allow from  $\frac{5}{8}$ " to 1" clearance between the halo ring and the patient's head (Fig. IV).




Fig. V


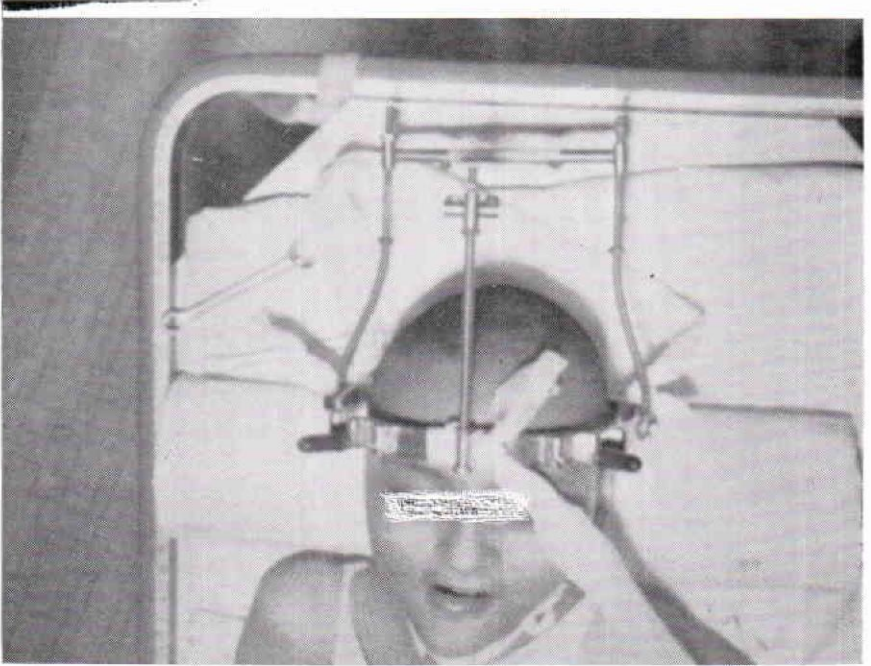


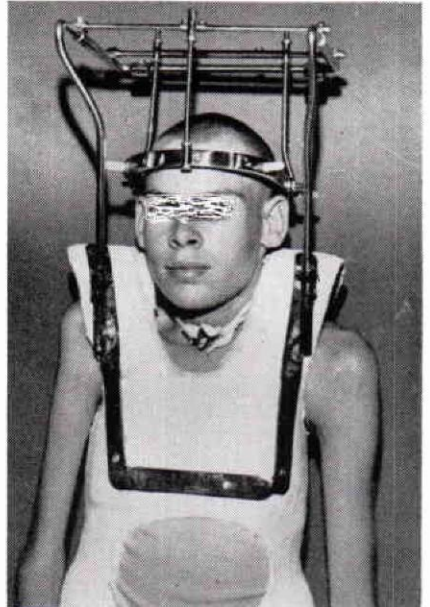
Fig. VI

The physician next applies the body jacket to the patient (Fig. V). It will be helpful if the orthotist can be present during the application of the cast to shape the mounting brackets to the cast (Fig. VI). The cast can be built up with plaster bandage in this area, which makes the final mounting easier. This is a respiratory patient who is receiving positive pressure through the tracheotomy during halo application.



The next operation is to attach the mounting brackets to the cast. This is done with 10-32 machine screws. Care should be taken to place the brackets parallel to each other. After the brackets are fixed to the cast and in proper alignment they are plastered over to give additional strength. Fasten suspension assembly to halo ring before the overhead support is shaped to insert into the mounting brackets (Fig. VII).

Many times, due to scoliosis, the head is not in line with the midline of the body, in such cases it is advisable to shape overhead supports so that all the medial-lateral adjustment is in the direction that you will be moving the head. (Fig. VIII)



The halo has about 4" medial-lateral adjustment and 4" to 6" vertical adjustment and anterior-posterior adjustment. It is always wise to allow as much adjustment as possible.

Shape overhead suspension to fit into mounting brackets and attach the suspension assembly. You can now adjust the halo to bring the head into the desired position. This adjustment is done under the supervision of the physician.

Make sure all set screws and nuts are TIGHT. They should all be checked periodically to make sure they are tight. Any looseness in the halo can cause necrosis around the skull pins.

\*Much of the credit for the design of the halo as used at Rancho Los Amigos Hospital should go to Jack Conry, C.O., Research Orthotist and Richard Young, C.O., Orthotic Instructor.

#### References

1. Crutchfield, W. G.: Skeletal traction for dislocation of cervical spine, report of a case. *Southern Surgeon*, 11, 156, 1933.
2. Hoen, T. I.: A Method of Skeletal Traction for Treatment of Fracture Dislocation of Cervical Vertebrae. *Arch. Neurol. and Psychiat.*, 36: 158-161, 1936.
3. J. Perry; V. Nickel: Total Cervical-Spine Fusion for Neck Paralysis. *Journal of Bone and Joint Surgery*, Vol. 41-A, No. 1, pp. 37-60, January, 1959.
4. Bloom, F. A.: Personal communication.

---

## OFFICE OF VOCATIONAL REHABILITATION

Washington, D. C.

Appointment of Dr. Robert L. Bennett of Warm Springs, Georgia, and James A. Brownlow, of Washington, D. C., to the National Advisory Council on Vocational Rehabilitation has been announced by Secretary of Health, Education, and Welfare Arthur S. Flemming. Both appointments, for unexpired terms, fill vacancies created by the recent resignations of two Council members.

Dr. Bennett succeeds Dr. Frank H. Krusen, who resigned to become Special Assistant for Health and Medical Affairs to Miss Mary E. Switzer, Director of the Office of Vocational Rehabilitation. Mr. Brownlow succeeds Gordon M. Freeman.

The 12-member Advisory Council reviews applications to OVR for Federal grants from sponsors of research and demonstration projects, and recommends approval of those which show promise of making valuable contributions to the rehabilitation of disabled persons. Miss Switzer is Chairman of the Council.

Dr. Bennett's appointment brings to the Council one of the outstanding leaders in the area of physical medicine and rehabilitation. He is Executive Director of the Georgia Warm Springs Foundation; Director of the Department of Physical Medicine, Emory University Hospital, in Atlanta; Chairman of the American Board of Physical Medicine and Rehabilitation; Past President, American Congress of Physical Medicine and Rehabilitation; and Consultant to the Georgia State Division of Vocational Rehabilitation.

Mr. Brownlow served previously on the National Advisory Council on Vocational Rehabilitation during 1955 and 1956. He is President of the Metal Trades Department, AFL-CIO, in Washington, D. C.