

# Prosthetic Habilitation of Infant Quadruple Amputee

JOSEPH SMERKO, C.P.\*\*

*Chicago, Illinois*

and

By CLAUDE N. LAMBERT, M.D.\*

*University of Illinois College of Medicine*

This child was first seen at the University of Illinois Amputee Clinic on August 8, 1957, when she was four months old. She was the third child in the family. The mother is Rh Negative and the father Rh Positive. She was a full term spontaneous delivery and at birth it was noted that she had bilateral hip disarticulation amputations together with a mid-humeral amputation on the right and a very high above elbow amputation on the left. (Fig. 1) By classification, she would be a bilateral upper humeral hemimelia and a bilateral lower complete amelia. Her heart and lungs and general systemic review was entirely normal except for the above described abnormalities. It was felt at this time that she was too young for prosthetic substitution.

At ten months of age, the child had been sucking on the finger bud of the right arm and using this as a pacifier as well as using the stump for gross functions. It was therefore decided to begin fitting the upper extremities with prosthetic replacements. This consisted of bilateral preflexed

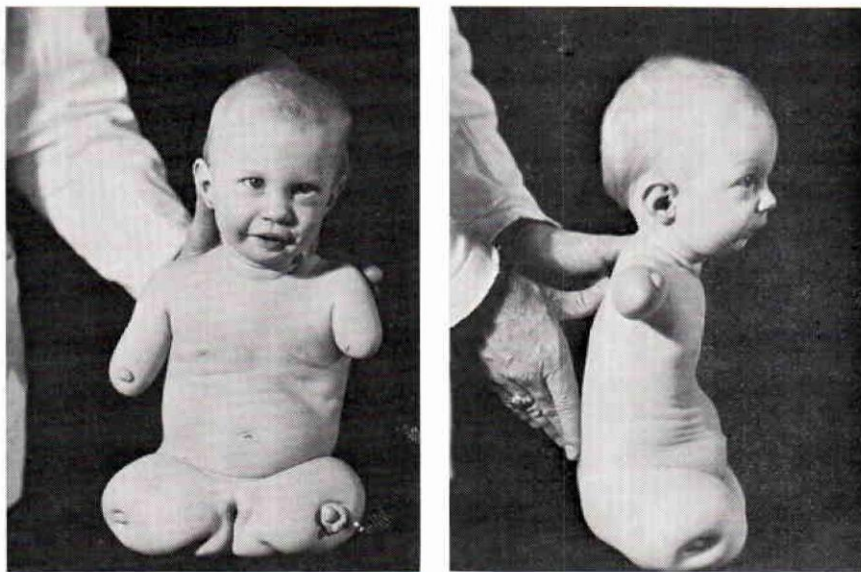


Figure 1

\* Dr. Lambert is Professor of Orthopedic Surgery, University of Illinois College of Medicine; Attending Orthopedic Surgeon, Research and Education Hospitals, University of Illinois; Attending Orthopedic Surgeon at the Presbyterian-St. Luke's Hospital; Lecturer in Orthopedic Surgery, Northwestern University.

\*\* Joseph Smerko, C.P.—Lake View Limb, Brace & Surgical Supplies Co., Chicago, Ill.

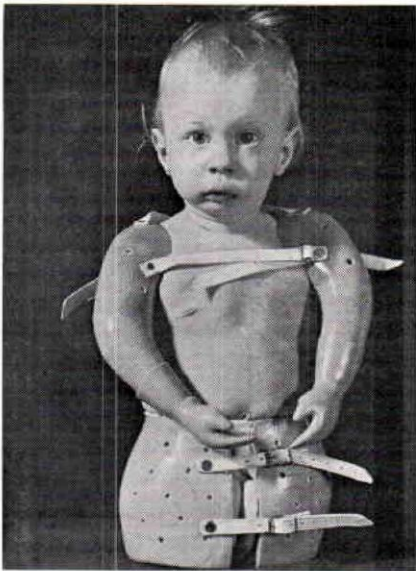


Figure 2

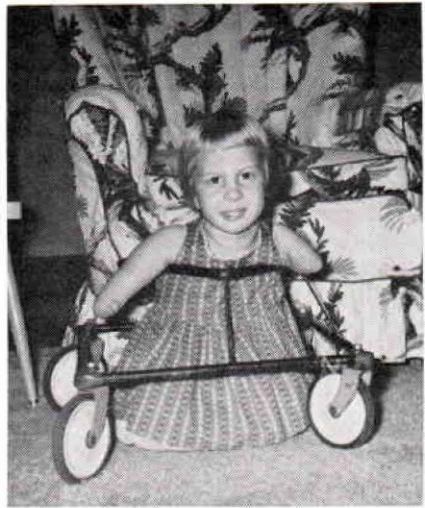

Figure 3

double-wall semi-rigid arms to which were attached plastic mittens.

After a short time some of the things she could do was wave a flag, bang on a xylophone with sticks, rattle rattles and pat her mittens like hands for a Pat-a-Cake game.

At the age of sixteen months, a model was made for a plastic pelvic support, (Fig. 2) inasmuch as she was unable to balance herself on the rounded buttocks and particularly since the addition of her upper extremity prostheses required her to sit in an upright position to attain optimal function. A plastic pelvic support with a flat bottom was constructed of a semi-rigid polyester resin, split in two halves and hinged in the posterior section for ease in applying, and a simple buckle and strap were used in the anterior section for attachment. After a fitting she was able to assume an upright position.

By the age of nineteen months, she was using the right upper extremity prosthesis very well and insisted upon having it on at all times. The mother mentioned that the finger bud on the right stump used as a pacifier, was creating a minor psychological problem when the arms were on. The left one was tight and had to be enlarged to allow her more use.

At this time it was felt that the plastic mitten on the right could be replaced with a 10 AW Hook and single control cable. She learned to open and close the hook immediately. However, her only objection was that she could not bring various objects to her mouth and she could not move about from place to place. To solve the latter problem, her father constructed a roller-type walker (Fig. 3) in which she could swing her body resting her axillas on the upper bars and move about in an upright position. Up to this time, her only means of moving about was rolling.

By the time the child was twenty-nine months of age, she had outgrown both upper extremity prostheses so that neither one fitted at all. The mother stated that the child asked to have the prostheses on because she had found she could do so many things with them that she could not do without them. A new upper extremity prosthesis was ordered to continue



with a 10 AW Hook on the right and a 10 X Hook on the left giving her bilateral control.

A short time after the delivery of the new arms, a 10 X Hook was tried on the right long arm stump and it was found to be of greater benefit than on the left. Now the child was able to pick up smaller objects such as puzzle pieces and she could scribble and color with pencils which she was unable to do with the plastisol covered hook on the right arm. We then used the 10 AW on the left short stump side. She was now also able to maintain her own sitting balance without the use of her plastic bucket support.

In October of 1960, a left 10 X was ordered for the short arm. It seemed now that the child accepted her arms and enjoyed working with them to the fullest as long as she was occupied with many interesting and varied projects. The length of time she wore them depended upon this and her dependency of being moved about. It was suggested that a therapist could help in varying the interests and techniques in using her arms. This proved to be very beneficial.

By January, 1961, this patient was using her upper extremity prostheses one hour or more a day and using both with equal facility. However, her prostheses were again becoming small and it was decided at this time to have a standard above elbow on the right with an outside elbow lock, and to continue with the left prosthesis for the present but to lengthen it with spacers at the wrist, thus maintaining her overall length. In February, 1961, she was using her new right prosthesis fairly well and learned to use her new elbow immediately. It seemed as though another new world unfolded

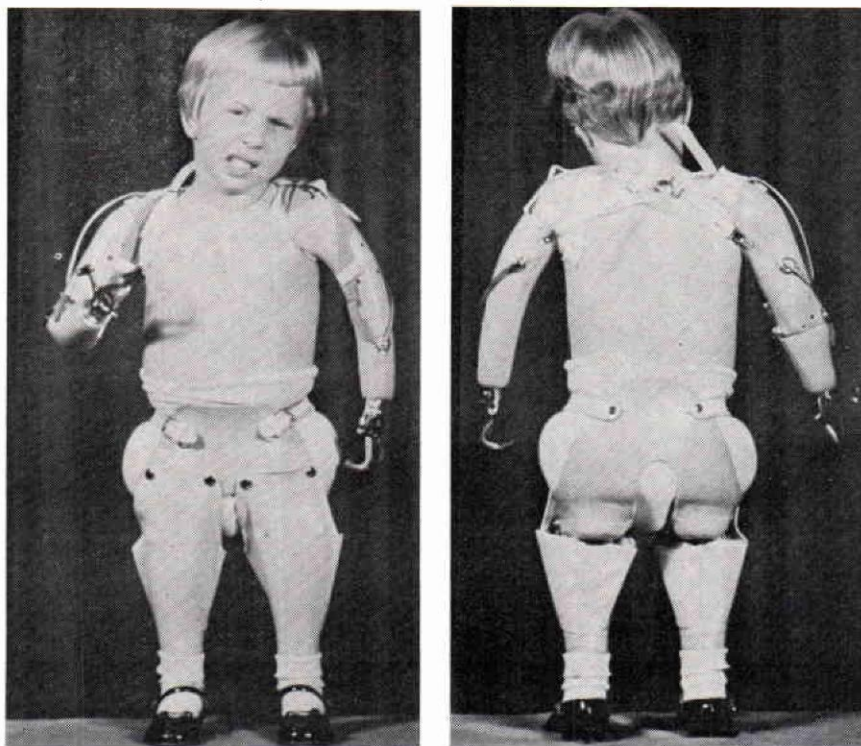


Figure 4

for her as she could now bend her elbow and bring objects to her mouth, and that more relearning had to be done.

At this time it was felt she was old enough, being practically four years of age, for us to begin the fabrication of lower extremity prostheses. Fundamentally these would be a Canadian hip disarticulation type with about a nine-inch leg piece, without knee joints, connected to bilateral SACH feet. This would be a preliminary stage so that when she became accustomed to this increased height, she could then be raised an additional nine inches and have knee joints added.

The socket was constructed with large teardrops on the lateral sides with adjustable straps fitted over the iliac crests. It was felt that this type of construction would accommodate growth much better than a split socket and also give more stability in walking.

In May, 1961, she received her bilateral Canadian hip disarticulation prostheses and from the very beginning did extremely well. (Fig 4) There was a question as to whether or not she should have one hip joint temporarily locked for stability but she did so well it was felt she could be trained without the locked hip joint.

On July 13, 1961, she was walking with her bilateral Canadian hip disarticulation prostheses with a pseudo four-point gait and maintaining her balance quite well with short crutches. One consideration was that she should be supplied with lighter weight crutches and secondly, that she soon have a new prosthesis on the left upper extremity which would have an actively operated elbow lock. On this side, due to the shortness of her humerus, she could have a conventional inside locking child size elbow.

At the time of this writing, the parents have informed us that the child is driving a battery-operated Go-Cart using her legs for regulating the speed and her right arm to drive. (Fig. 5) She is also moving about to all parts of her home without any assistance.

