

Translation and Abstract Service

Editor's Note: A translation and abstract service for members and other readers of the *Orthopedic and Prosthetic Appliance Journal* was authorized by the Directors of the American Orthotics and Prosthetics Association in November, 1965. This service will provide for the reprinting of translations of prosthetic and orthotic articles from foreign periodicals, and summaries of articles from medical periodicals, and will offer literature of value to Certified Orthotists and Prosthetists, AOPA members, and interested readers.

The Abstract and Translation Committee is composed of:

William Tosberg, New York, N. Y., *Chairman*

Robert O. Nitschke, Syracuse, N. Y.

Camille Corriveau, Montreal

Siegfried Paul, New York, N. Y.

Nunzio Pulizzi, Williamsport, Pa.

Laurence Porten, Pittsburgh, Pa.

W. N. Peterson, Montreal

Fred Karg, Hollywood, Calif.

W. B. Peterson, Montreal

Siegfried Jesswein, Birmingham,

Jesus Nunez, Santa Ana, Calif.

Mich.

Donald Strand, Oakland, Calif.

Kurt Marschall, Syracuse, N. Y.

With this issue, the first two translations (by AOPA members Laurence Porten and Siegfried Jesswein) are made available to our readers. The *Journal* wishes to express its appreciation to the editors of *Orthopaedie-Technik* and to the German Association, Orthopaedie Chirurgiemechaniker und Bandagisten Handwerk, for permission to publish these translations.

Functional Treatment of Infant Spinal Deformities With a New Bandage (Harness)*

By MANFRED KALLABIS, M.D.

Munich, West Germany

Translated by LAURENCE PORTEN, C.P.O., O.M.M.

(Orthopedic Master Mechanik)

Pittsburgh, Pennsylvania

The most widely used treatment of spinal deformities to date is the application of plaster casts, especially plaster beds in conjunction with physiotherapy. However, this method lacks efficiencies which are pointed out as:

A too rigid fixation of the spinal column which restricts needed activity and leads to atrophy of the muscles and bones. The use of straps to tie the infant's legs and arms to the cast appears barbaric to the parents.

Therapeutic provocations such as brushing and tickling on the outside of the curvatures soon will tire the children and do not provide the expected results.

The making of a corrective plaster bed requires the help of two to three people, two of whom have to concentrate on the correction of the spine, and sometimes medication is necessary to quiet the baby. Also, due to rapid growth, the casts have to be replaced every 4 to 6 weeks.

In spite of the best care and attention, it is impossible to avoid soilage of the cast with excrement and urine.

* Translated and reprinted with the permission of the author and the publisher from *Orthopaedie-Technik*, Wiesbaden, Germany, Heft 8: August, 1964.

Due to hygroscopy of the plaster of paris to attract water, the plaster bed is always cool and the children are bound to have colds, and the parents neglect to put them into the beds. If the children are too warmly dressed to avoid colds the plaster beds, which are molded to the naked body, do not fit properly any longer and the correction is practically nil.

In any case, an exact ambulatory treatment in the parents' home is troublesome and very few parents follow doctor's orders systematically. Stationary treatments must be done in hospitals, which are expensive, and a new method is sought which eliminates these difficulties.

The author claims to have developed a simple but effective bandage (harness) which permits a permanent functional treatment of spinal deformities in the breast region of infants. With this bandage it is possible to correct the dorsal scoliosis at the vertex of the vertebrae by rotating the pull direction without disturbing all other normal movements of the spinal column in the upper and lower region.

Note: The following illustrations were supplied by Dr. Kallabis and received by Mr. Porten just as this issue of the *Journal* was going to press. At Mr. Porten's suggestion, the new illustrations and captions are substituted for the illustrations in the article as originally published in *Orthopaedie-Technik*.

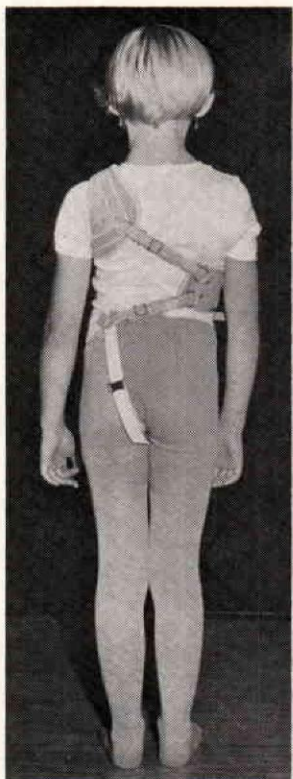

Figure 1



Figure 2




Figure 3

Figures 1 - 3—An 8-year-old child fitted with the bandage. It is fitted and worn over underwear, is practically invisible, and does not restrict normal movement.



Figure 4



Figure 5

Figures 4 - 5—The effect of the bandage on a $3\frac{1}{2}$ -year-old boy, showing the reverse rotation of vertebrae affected by scoliosis.

In summary, as long as the bandage is applied, the child will retain its freedom of movement above and below the vertex of the scoliosis, and extension and expansion, stretching and bending, are unrestrained and the muscles will not suffer from atrophy.

Description: of the Scoliosis Bandage

The construction of the bandage is very simple and four different sizes are sufficient for individual curvature treatments from infancy to approximately five years of age. The bandage consists of:

(a) A conical, funnel-shaped shoulder harness made from leather or durable felt and covered with soft leather which fits snug to the shoulder. A strong trapezoid-shaped elastic webbing with metal rings in front and back is fitted into the shoulder harness.

(b) A chest pad (pelotte) made from felt and covered with soft leather, with an adjustable elastic web fastened to the top of the pad.

(c) Four adjustable leather bridle straps, the ends of which are connected by metal rings to the pad in a criss-cross fashion. The free ends have a hook device and connect into the pad rings. Two straps are always used together to connect the shoulder harness with the chest pad (pelotte) and the chest pad with the pelvis harness (sling).

(d) The pelvis sling is made from two simple web straps which fit in a semicircle, pass through metal rings vertically at the ends together, and are moveable. The web strap which applies variable pressure to the symphysis is adjustable in gradual steps.

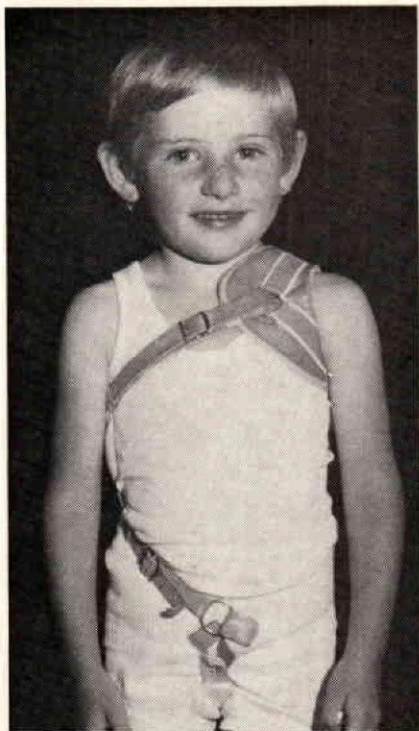


Figure 6

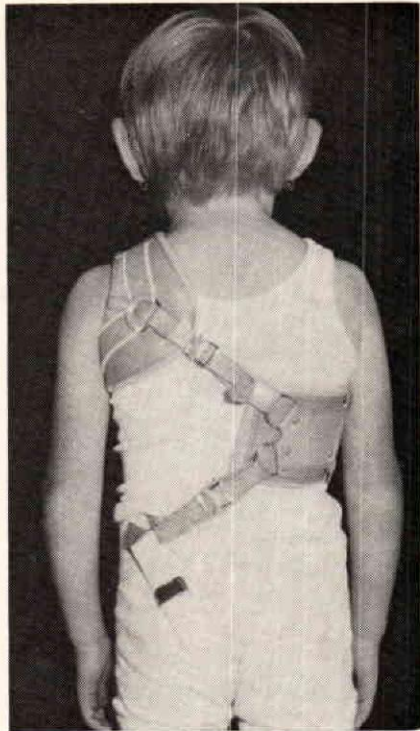


Figure 7

Figures 6 - 7—The bandage fitted to a 5-year-old girl. Note that the pelotte (pad) does not apply pressure from the side, but from below the humpback to secure the right correction.

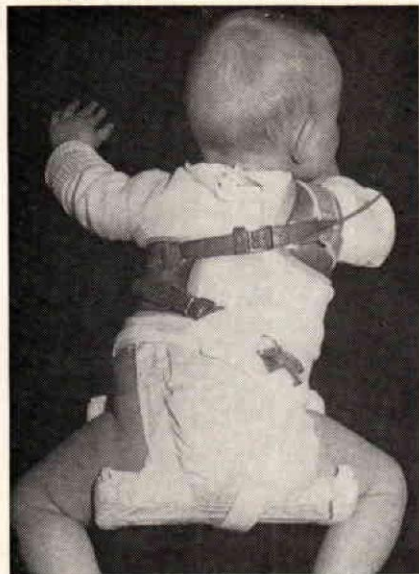

Figure 8



Figure 9

Figures 8 - 9—The bandage applied to a 6-month-old infant with a congenital hip luxation in addition to a large C-shaped scoliosis. The pictures demonstrate that both afflictions can be treated at the same time without restricting the child's normal movement.



Figure 10



Figure 12




Figure 13

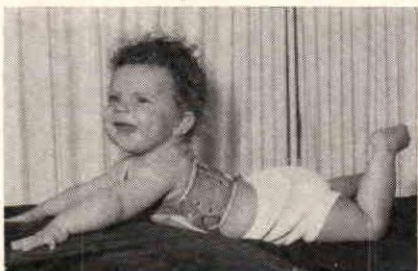

Figure 11




Figure 14

Figures 10 - 14—Five photographs of an infant playing with his brother and sister offer further proof of the value of this new correction bandage. The belly position is particularly valuable since it increases the effect of the reverse rotation of the bandage on the afflicted vertebrae during active play.

Application of the Bandage

The shoulder harness (a) will be applied to the outside of the scoliosis and the chest pad (pelotte, b) to the opposite side of the chest below the armpit. The ventral and dorsal bridle straps are hooked into the shoulder harness rings and tightened by means of the buckles until the pelotte fits snug to the body and the armpit.

The pelvis sling is applied next in such a fashion that the horizontal web strap fits above the crest of the ilia and the vertical strap between the legs and over the symphysis. The two lower bridle straps are hooked into the rings like the ones on the shoulder harness and tightened by means of the buckles until the chosen reversed scoliosis correction is accomplished.

The first fitting and adjustment should be done by the attending physician and an X-ray control is advisable. Further application and re-

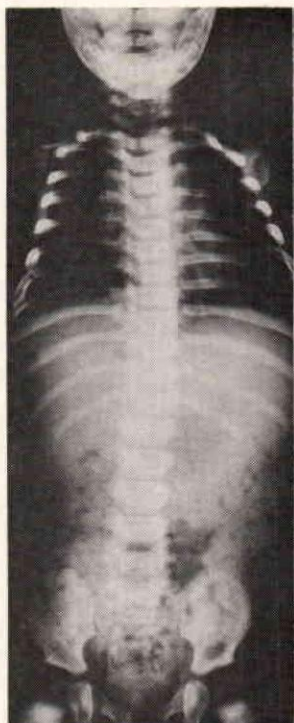


Figure 15

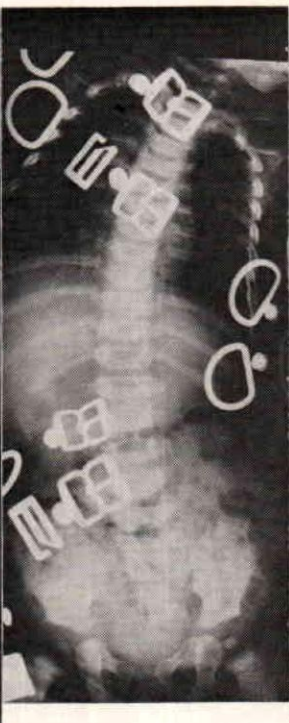


Figure 16

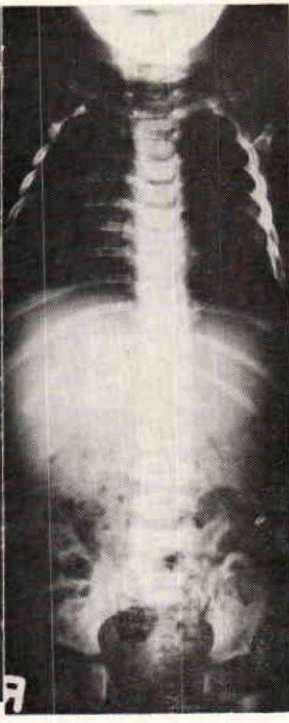


Figure 17

Figures 15-17—(a) A reduced X-ray picture shows a slight C-shaped infant scoliosis with a slight torsion and rib hunchback. (b) The same scoliosis curvature reversed by the new bandage. (c) Same scoliosis after 2 months treatment with the bandage. Attention is called to the fact that the scoliosis correction has improved, but the control was overlooked and delayed, and the result is a reversed thoraxes-symmetry.

removal of the bandage by laymen is simple. If diapers have to be replaced, only the front pelvis strap has to be unhooked, and the baby's leg can be pulled out of the leg sling. For removal of the whole pelvic harness, the second hook which connects the front strap and shoulder harness must be unhooked. To restore the previous position, both hooks are snapped on again and nothing can go wrong.

It has been our experience that all the children fitted with the new scoliosis bandage get used to it in a short time without changing their daily habits. We are of the opinion that treatment and therapy of dorsal scoliosis in infant cases can be administered in a shorter time and more cheaply and comfortably for both the children and the parents.

Future treatments (except for special cases) should be in the hands of accredited orthopedic doctors whose main task is to keep control over the proper adjustment of the bandage, and with the help of X-rays to reach the desired and attainable correction. The parents who are in charge of the child should bring him regularly to the doctor's office.

Due to our past experiences we feel it is possible to have older children fitted with this bandage just as long as the process of growth is not finished, as this will at least restrict the developing scoliosis and perhaps improve the condition until time for corrective surgery.

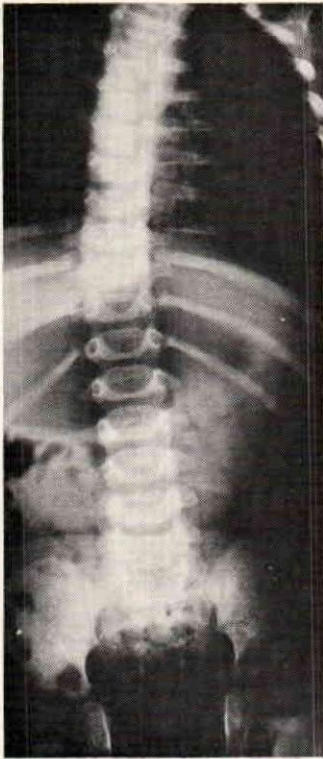


Figure 18

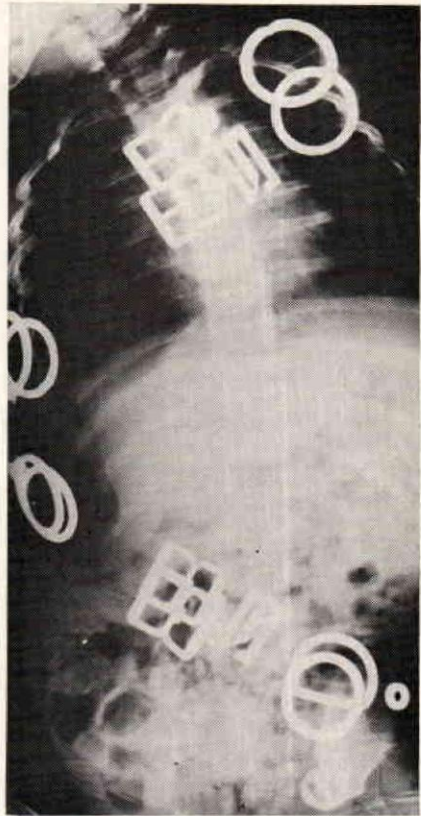


Figure 19

Figures 18 - 19—(a) A more pronounced C-shaped scoliosis of a year-old infant. (b) The same scoliosis after bandage has been applied and the reverse rotation at the vertex and its fixation is clearly visible.

Summary

Preliminary report about the introduction of a newly-designed bandage or harness to influence or reverse the rotation of the vertebrae which are affected by scoliosis. This bandage will allow the child, without hindrance, every normal movement like sitting, standing, running, etc.

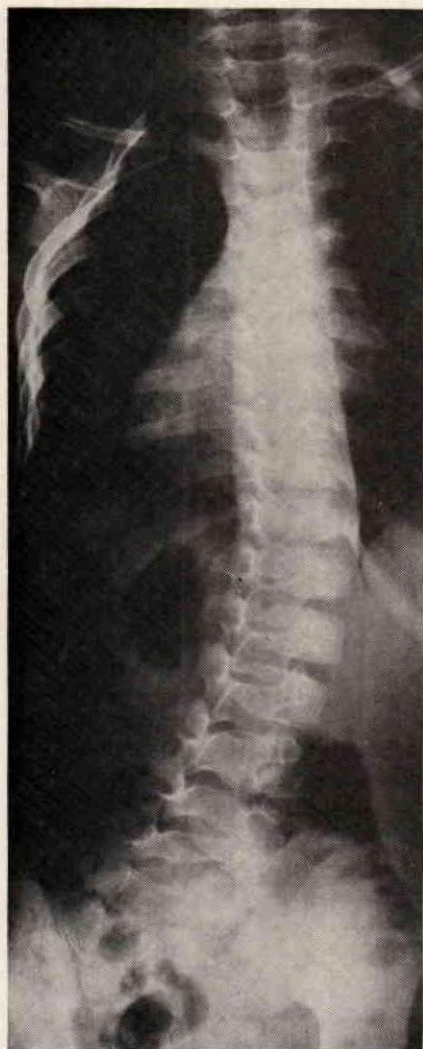

Figure 20

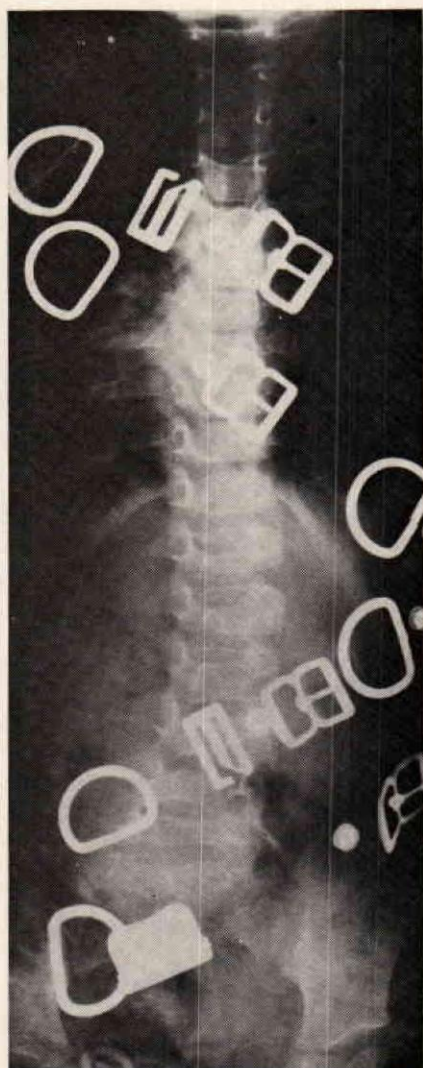


Figure 21

Figures 20 - 21—(a) A severe lumbar scoliosis with torsion caused by transitional disturbances—incomplete curve conclusion—of the last lumbar vertebrae of a 4½-year-old boy, taken in standing position. (b) The same scoliosis just after application. Since the scoliosis is loose and slack, the immediate corrective effect of the bandage is clearly noticeable.

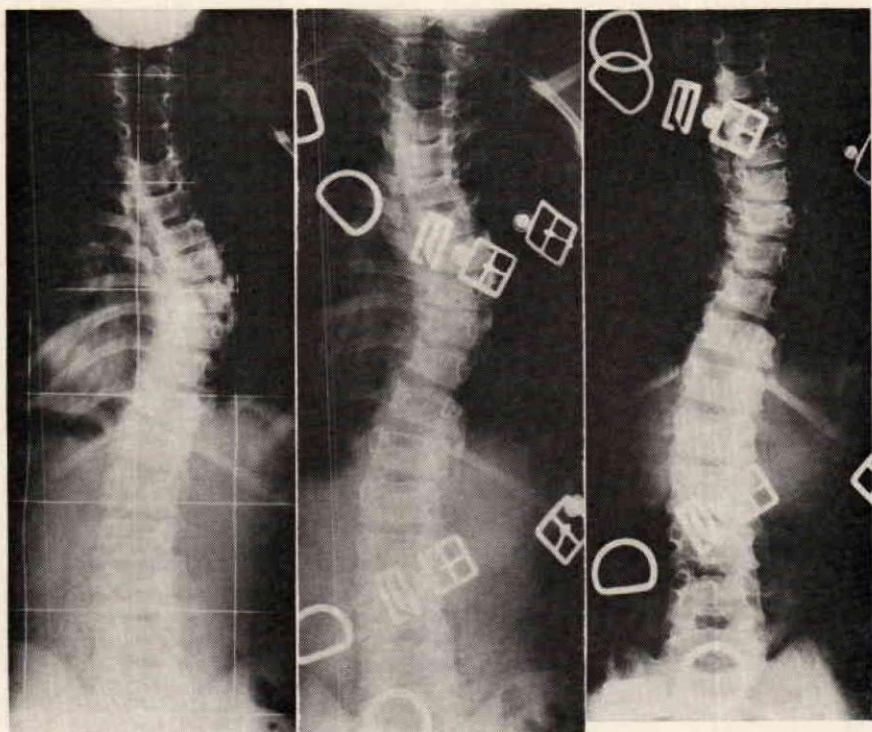


Figure 22

Figure 23

Figure 24

Figures 22 - 24—(a) A severe thoraxal scoliosis with torsion and vertebrae deformity of an 8-year-old boy. (Pictures taken in standing position). (b) The same scoliosis just after application of the bandage, with slight improvement already showing. (c) The same scoliosis spinal column 4 months later, showing the improved erect position which is credited entirely to treatment with the bandage.

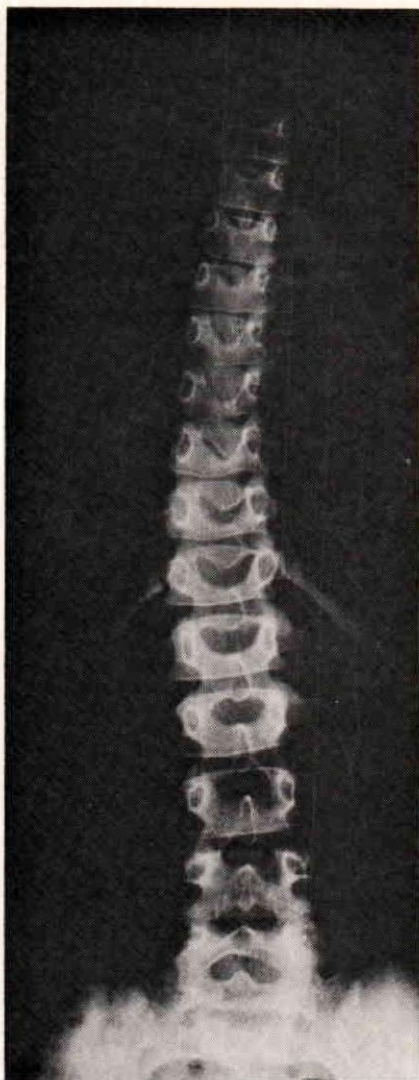

Figure 25

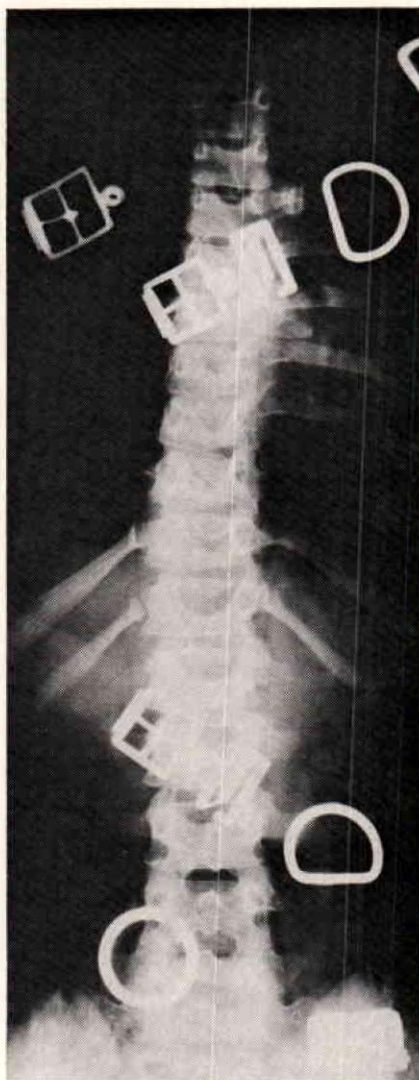


Figure 26

Figures 25 - 26—(a) A beginning thoraxal scoliosis in a 7-year-old girl. (Pictures taken in standing position). (b) The same scoliosis after 4 weeks of treatment with the bandage. A slight loosening of the scoliosis may be noted. Goal of the treatment is to arrest the progression of the scoliosis and achieve a more favorable situation for a later operation, or eventually to avoid such an operation entirely.