

The Design of a New Style Ischial Weight-Bearing Brace for Use in the Treatment of Legg-Perthes Disease

Melvin J. Glimcher, M.D.,* Eric L. Radin, M.D.**
and Michael M. Amrich, C.P.***

Orthopedic Research Laboratories, Harvard Medical School, at the Massachusetts General Hospital, and the Rehabilitation Clinic Liberty Mutual Medical Service Center, Boston, Massachusetts

This work was supported by the Liberty Mutual Insurance Company

Purpose

The principal of protection of the femoral head during avascular necrosis (Legg-Perthes Disease) results from the observation that the natural end stage of this disease, if untreated, is flattened, enlarged femoral head. The late osteo-arthritic changes that these patients frequently develop are probably the result of a loss of congruity between the fem-

oral head and acetabulum. While in the process of healing, the bone in the femoral head is porotic and not able to take the usual stresses of weight-bearing. Furthermore, this disease affects children in a period of relatively rapid growth. The synovial effusion that accompanies the disease usually causes some subluxation of the femoral head, removing it from the acetabulum, allowing the

* Edith Ashley, Professor of Orthopedic Surgery, Harvard Medical School; Senior Lecturer, Department of Mechanical Engineering, Massachusetts Institute of Technology; Consultant, Rehabilitation Clinic, Liberty Mutual Medical Service Center, Boston, Massachusetts.

** Assistant Professor of Orthopedic

Surgery, Harvard Medical School, Lecturer, Department of Mechanical Engineering, Massachusetts Institute of Technology; Consultant, Rehabilitation Clinic, Liberty Mutual Medical Service Central, Boston Massachusetts.

*** Chief Prosthetist, Rehabilitation Clinic, Liberty Mutual Medical Service Center, Boston, Massachusetts.

head to grow in an incongruous fashion. Concomitant x-rays and photographs taken of cadaver specimens demonstrate that the articular surface of the femoral head is well-covered by the acetabulum in all positions.¹ The advantage of abduction is not better coverage but rather allowing the seating of the femoral head more securely within the acetabulum in the presence of effusion, permitting its growth to be moulded by the socket.

Muscular forces about the hip contribute a much greater share of the load borne by the joint than does body weight. Inman² was probably the first to suggest that the abductor muscle group contributed the major share. He theorized that the forces acting through the hip joint approximate two and a half times body weight. More recently Paul,³ calculating the intra-articular force by analyzing displacement of legs in gait films, and Rydell,⁴ by measuring pressures transmitted through a specially instrumented femoral head prosthesis, clearly substantiated that hip intra-articular pressures are far in excess of body weight. Their figures, in fact, tend to suggest that Inman's values were on the low side.

The multiplicity of methods now in use in the treatment of Legg-Perthes Disease bespeaks the lack of any truly satisfactory means. Strict bed rest, while removing body weight from the hip, still allows muscular contractions as the patient moves around in bed. The Snyder Sling again gives the patient something to fix against. Furthermore, it is an extremely easy device for a child to overcome. He merely needs

to flex the opposite knee in order to get the affected side foot on the ground for full-bearing.

The classical patten-bottom brace, developed empirically, consists of a full-ring Thomas splint, thigh and calf straps, and a rubber patten at the bottom of the brace. The foot is elevated above the patten by building the other shoe up from two and a half to three and a half inches with a lift. Weight is borne through the ring of the splint, from the ischium directly to the patten, bypassing the hip joint. In order to keep the foot within the brace and out of equinus a strap goes from the heel of the shoe to the top of the patten. The circumferential supports as well as the strap gave the child many points upon which to fix the leg in order to contract the muscles about his hip.

It has been our clinical observation that the old style patten-bottom brace was inadequate because it did nothing to eliminate the muscular forces about the hip (Fig. 1). The good results probably derive

NORMAL HIP

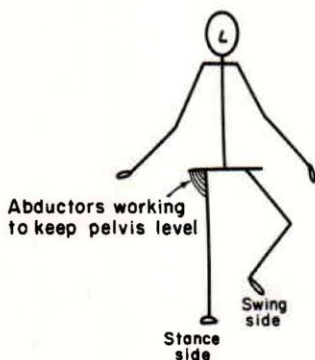


Figure 1A

Diagram of normal abductor muscle function. The stance side abductors contract to maintain the pelvis level.

OLD STYLE BRACE

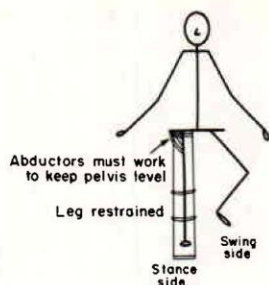


Figure 1B

In the "old style" patten-bottom brace the abductors can still function normally as the leg is restrained.

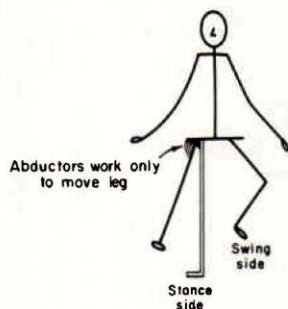
from the encumbrance of the child with the apparatus. It is clear that to prevent muscular forces acting about the hip joint either the abductor muscles must be fixed in length or the affected leg be completely free.

We have approached the problem of redesigning this brace from an experimental point of view. An attempt was made to record direct inter-articular pressures from the hip joint of a chimpanzee which had been taught to walk upright and fitted with braces. However, it became apparent that the chimpan-

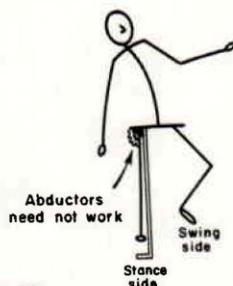
zee's gait pattern was so different from man's that valid conclusions applicable to the human situation could not be drawn.⁵ We have thus been forced to rely on EMG recordings of muscle activity during gait to substantiate our design changes.

Our first major change was an attempt to support the opposite pelvis so that the affected-side abductor would not be triggered into firing. It is the slight drop of the pelvis on the opposite side which stretches the muscle and triggers its contraction. Substituting a laminated plastic quadrilateral socket for the Thomas ring for better support, we were able to successfully support the pelvis with a second quadrilateral socket held by a strap cinched over the shoulder. We found, however, that the tension on the strap and the pressures applied to the ischial tuberosity by the support socket were really so great that only very small children could tolerate it. We also did away with the strap from the heel of the shoe to

POGO STICK BRACE



POGO STICK BRACE



Figures 2A & 2B

In the Pogo Stick Brace, although the abductors can contract they can no longer function to level the pelvis. Patients rapidly adjust to the fact that contracting their abductors is no advantage in braced gait. The abductors quickly become silent after their effectiveness has been lost. Balance is achieved by shifting the body weight over the braced side.

the patten and replaced it with a dorsiflexion spring brace, eliminating this point of possible leg fixation.

We then changed our principal attack to focus on attempting to keep the affected leg completely free (Fig. 2). If the leg is free there can be no way to stabilize it and fire the abductors. We accomplished this with a single medial upright, eliminating the calf or thigh straps and adding an extremely loose calf ring (Fig. 3). The superior brim of the lateral wall of the quadrilateral socket was extended to the iliac crest, and an oblong cut-out made distal to the greater trochanter (Fig. 4).

Balanced on the end of a single medial upright without anything to fix the leg on made it difficult to forcefully contract the abductors. EMG studies bore this out. We found, however, that putting pants on over the brace provided the male patients with a means of stabilizing the leg (Fig. 5). It was thus necessary to insist on extremely wide legged pants ("bell bottom trousers") in order to prevent the leg from being fixed. The efficacy of this model has been borne out both in adult tests where the adult volunteer has felt a sense of freeness of his leg which disappeared when the leg was fixed to the upright with straps (Fig. 6).

This brace was first made for a juvenile patient in March of 1964. Since that time 24 children ranging in age from 4 to 12 (Figs. 7 and 8) have been provided with the device. Although it is much too early to draw any conclusions relative to the treatment of Legg-Perthes Dis-

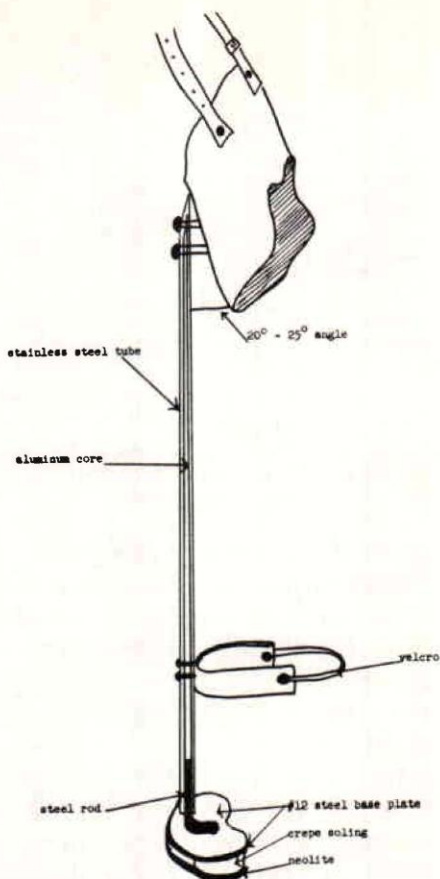


Figure 3

Diagram of the Pogo Stick Brace. Note the large loop to allow free leg motion and the abduction of the socket.

case on the basis of our experience so far, the study is continually expanding. Plans to utilize the brace for adults with hip fractures are also under consideration.

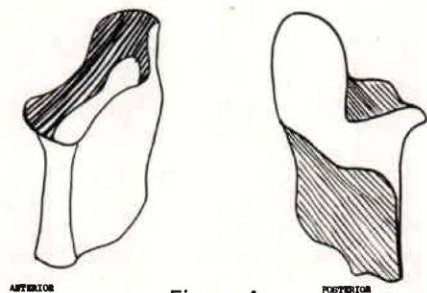


Figure 4

Diagram of the quadrilateral socket. Note the lateral wall cut-out.

TIGHT PANTS

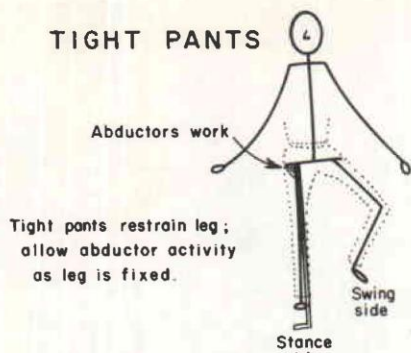


Figure 5

Tight pants over the Pogo Stick Brace act to restrain the leg abolishing the muscle silencing action of the brace.

Since the brace was first introduced there have been a few attempts to imitate it. We have been impressed that the imitators have not fully grasped the significance of the free-hanging leg and have concentrated only on the cut-out lateral wall of the socket and a single up-right. We hope that this communi-

cation will clarify these important points for all. The following information is provided as a step-by-step procedure for measurement, fabrication, and fitting of the brace.

BRACE FABRICATION AND FITTING

Measurements

Normal brace tracings, lengths, widths, and circumferences are taken of the affected extremity.

Additional Measurements

a) Anterior-posterior measurement taken from the adductor longus tendon to the ischial tuberosity.

b) Medial-lateral measurement taken from the adductor longus tendon to the greater trochanter.

c) Mid-calf height for band of spring toe pickup splint.

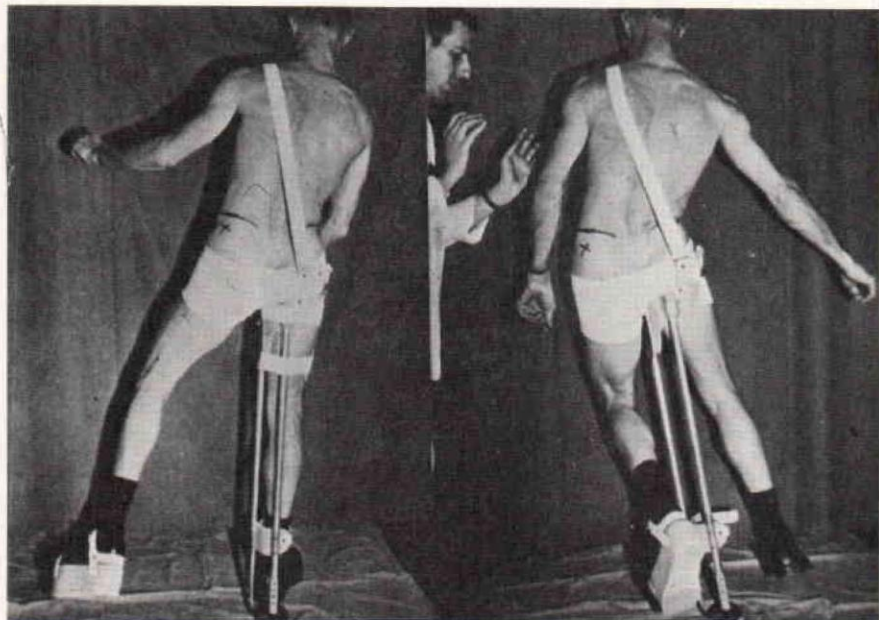
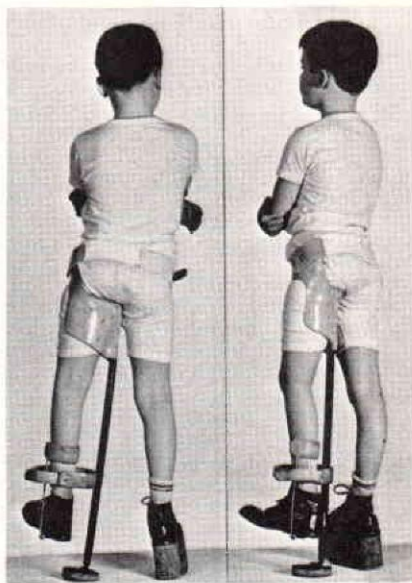



Figure 6

With a strap around the upper leg, it is relatively easy to balance on the brace.

With the strap removed, and the leg free, it is no longer possible.



Figures 7A & 7B

Patient fitted with a Pogo Stick Brace on the right. Note the bell-bottom pants in Figure 7A.

d) Top of shoe height for ankle retainer band position. Normal shoe extension height must be added to this for proper attachment of brace.

e) Shoulder loop suspension length is taken from the anterior perineum level over the opposite shoulder and back to the greater trochanter.

f) Ischium to bottom of shoe plus height of shoe extension for brace length.

Casting

a) Small children may be casted by hand moulding technique. Brims and/or brim stands can be used, if sizing can accommodate thigh circumference.

b) Procedure:

1. Patient stands with normal foot on 4" block and affected extremity abducted 25°-30°. Assistance may be necessary for balance.

2. Cast sock is applied to include the complete pelvic area of the af-

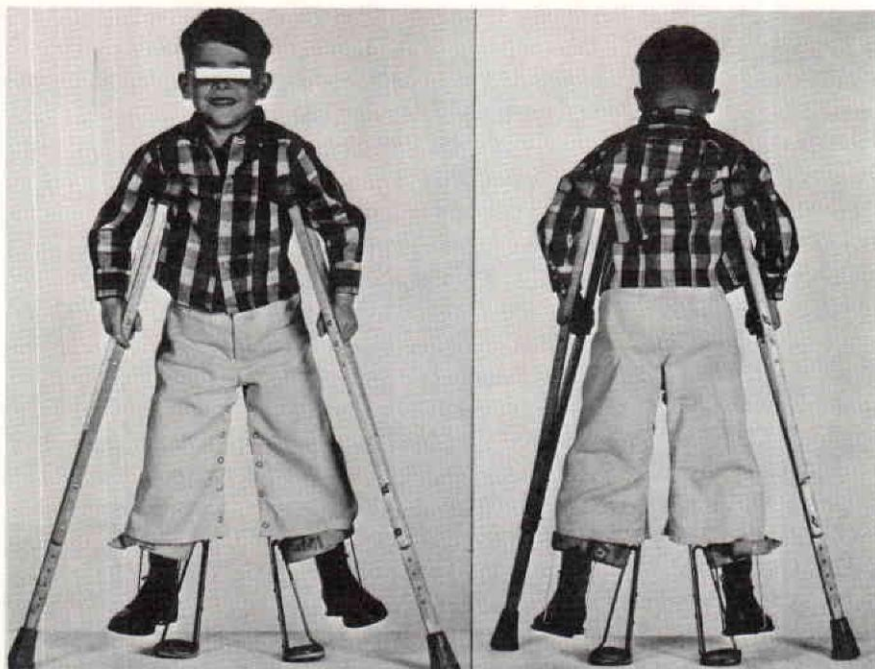fected side. For small children it is better to fashion a pair of briefs from 8"-10" stockinette.

3. Indelible markings are made on the sock at the greater trochanter, ischial tuberosity, crest of the ilium and distal brim line.

4. Using 4"-6" elastic or fast setting plaster of Paris bandage, wrap extremity laterally up to iliac crest, and distally from the ramus about 8". If a casting brim is used, the plaster wrap must be carried above the brim to the iliac crest.

5. If hand casting, thumb and flat of hand are used respectively to shape the scarpas to ischial tuberosity level. Right hand is used for right casts with opposite hand used to mould cast into the iliac fossa area.

6. The negative cast is closed on the end, and extensions are made anteriorly, medially, and posteriorly in preparation for vacuum lamination.



Figures 8A & 8B

Patient with bilateral Legg-Perthes Disease fitted with Pogo Stick Braces bilaterally.

Cast Modifications

a) Cast is altered in usual manner according to measurements.

b) AP shaping to measurements is critical. Ischial seat must be altered to accommodate the degrees of abduction and should be perpendicular to the floor in stance position.

c) Superior lateral modification of cast is done by making cast concave in iliac fossa area.

d) Cast is prepared for vacuum lamination.

Lamination

a) Material set-up:

1. One layer of $\frac{1}{2}$ ounce dacron felt.

2. Four 2" strips of fiberglass reinforcement around complete upper portion of brim. Add several layers of 4" width fiberglass to medial wall of lay-up.

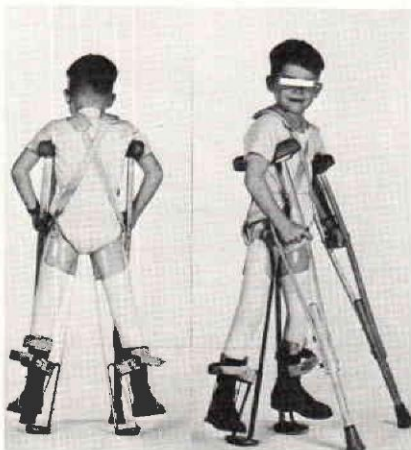

FIG. 8B

3. Three or four layers of nylon stockinette.

b) 90% rigid-10% flexible resin mixture. 600-800 grams will be needed for child-size brims. Epoxy resin is suitable for heavy weight use.

Trim Line of Brim

a) Medial Wall—Extends about 6"-8" distally for attachment to medial upright.

b) Anterior Wall—Trimmed similarly to AK socket with adequate flare to maintain ischial tuberosity on seat.

c) Posterior Wall — Trimmed 1½"-2" below ischial seat and flared into medial wall.

d) Lateral Wall—Proximal trim line is distal to iliac crest and anterior superior iliac spine and blended into anterior and posterior superior brim. Lateral wall is removed in inverted U shape from level of greater trochanter distally and blended into the anterior and posterior walls.

Components and Assembly of Brace

a) Brim with abduction cut-out

b) Medial support:

1. Stainless steel tube (T304, ¾" OD, .035-20GA wall.

2. Aluminum tube (⅝" OD-⅜" ID).

a) Fits into steel tube for added strength .

3. Tube and insert extend from superior medial wall distally to base plate attachment.

a) Tube and insert are flattened at proximal attachment to brim to avoid bulk.

b) Brim is temporarily attached with two #8 copper belt rivets at 5° flexion and 25° ab-

duction angle. Wooden wedge is used to maintain angle.

4. Steel rod attachment to base plate (⅜" x 10"):

a) Distally a 1½" right angle bend is welded or silver soldered to steel base plate—medial to mid-line.

b) Upper part inserted into tube assembly and attached with four SS screws 8/32" x 7/16" ½" apart for height adjustment.

5. Steel base plate #12 gauge spring steel:

a) Cut about 2½" x 4" and corners rounded.

b) After attachment to steel rod, leather is glued and riveted for base of soling.

c) ½" crepe soling is glued to leather.

1. Crepe is sanded medially to tilt plate an additional 5°.

d) Neolite or some hard wearing sole is glued to crepe.

6.) Ankle band retainer 2" x 10-12" #16 gauge spring steel):

1. Bend in J shape:

a) Posterior part of band approximately 2½".

b) Medial part of band approximately 3".

c) Anterior part of band approximately 6".

2. Laterally, a loose velcro closure about 12" long is made through a rectangular bar.

3. Band is dipped in plastisol or leather covered.

4. Retainer is attached with two steel rivets at pre-measured height about 8"-10" from floor.

Brim is permanently attached to medial upright at correct angle.

a) Epoxy filler is used for firm attachment.

b) Buckles are riveted to brim for shoulder loop.

1. Anterior attachment at mid-brim level of seat and lateral attachment midway between superior trim line and greater trochanter.

2. Foam rubber shoulder pad should be made for loop.

Spring Wire Pickup Splint

a) Standard type used to maintain foot in moderate dorsiflexion. Since non-weight bearing, tension of spring may have to be lessened to avoid heel riding out of shoe.

Normal Shoe Extension

a) Recommend $3\frac{1}{2}$ "-4" buildup of lightweight material.

b) Bottom of extension sanded on medial aspect to place foot into

c) $\frac{1}{4}$ " crepe soling and hard rubber sole are glued to extension. slight eversion.

d) Extension can be stained and water-proofed.

Wearing Apparel

a) Loose clothing should be worn over brace.

1. For female patients, a dress or skirt would be better to avoid restriction of movement of the involved extremity.

2. For male patients, trousers must be altered in an exaggerated bell-bottom fashion. The outside seam of the trouser leg is opened from top to bottom. An appropriate triangular shaped piece of material is then sewn to this seam to allow free motion of the extremity. Trousers or slacks should not extend below the ankle band.

Fitting, Checkout, and Ambulation

a) Application of brace:

1. Protective sock or stockinette must be worn.

2. Brace is applied by putting foot through brim and pulling brim up to perineal level.

3. Shoe with spring splint is put on and positioned into retainer band with loose velcro closure.

4. Normal shoe and shoulder loop suspension are put on.

b) Check-points:

1. In stance position, check for level iliac crests. Also check for height of affected shoe from floor. Should be about same height as shoe extension.

2. Location of greater trochanter—should allow free abduction of extremity.

3. Retention of foot in retainer band.

a) Loose velcro closure so that foot is free and only light contact is made with velcro.

4. Shoulder loop suspension should be snug to support brace and maintain ischial tuberosity on seat.

Initial Ambulation

a) Patient should use two crutches for balance.

1. Children will usually regain balance with brace in about two weeks and discard crutches.

b) Patient should ambulate with broad base and concentrate on abducted gait with brace.

c) Bilateral brace wearers should use two crutches at all times, however, some children may develop good balance and discard crutches indoors.

REFERENCES

1. Hammon, B. T. and Charnely, J. The Sphericity of the Femoral Head. *Med. & Bio. Ergng.* 5:445-453, 1967.
2. Inman, V. T. *Functional Aspects of*

- the Abductor Muscles of the Hip. *J. Bone Joint Surg.* 29A:607-619, 1947.
3. Paul, I. P., Bio-engineering Studies of Forces Transmitted by Joints, in *Bio-mechanics and Related Bioengineering Topics*. R. M. Kenedi (ed.). Pergamon, London, 1965, pp. 359-368.
 4. Rydell, N. W. Forces Acting on the Femoral Head Prosthesis. *Acta Orthop. Scand. Suppl.* 88, 1966.
 5. Radin, E. L. and Amrich, M. M. Limitations of Chimpanzees as Subjects in Brace Design Experiments. *Bull. Prosth. Res.*: 12-10:205-212, 1969.