

A New Material in Orthotics and Prosthetics

MELVIN STILLS, C.O.
A. BENNETT WILSON, JR.

Thermosetting plastics were first introduced into prosthetics for fabrication of sockets and structure components for artificial arms about 1952 (3). Although thermosetting plastics have disadvantages, their use in both upper- and lower-limb prosthetics has grown to the point where it is now rare to see a socket formed of any other material. However, when orthotists and engineers tried to use thermosetting plastics in orthopaedic bracing they found that the laminates fail quickly when subjected to the repeated bending loads that occur during use of functional lower-limb orthoses.

Although Volume I of the *Orthopaedic Appliances Atlas* (7), which was published in 1952, contains a detailed description of the use of vacuum to form cervical orthoses from the thermoplastic, Plexiglass, it was not until about 15 years later that serious efforts were made to use thermoforming of sheet plastics in fabrication of orthoses or prostheses.

The first reference to thermoforming sheet plastics in lower-limb orthotics seems to be a brief article by Gordon Yates that appeared in a 1968 issue of *Orthopaedics, Oxford* (9), and in which he describes a simple ankle-foot orthosis made of polypropylene. Stimulated by presentations made by Dr. Yates during a visit to North America in 1969, research

and development groups in Canada and the United States began using sheet plastics, especially polypropylene and polyethylene in serious experimental work (1,2,4,5,6). Clinical application of the results of these studies has spread gradually, and these techniques are now taught in the formal prosthetic and orthotic education programs (8).

Because of a combination of characteristics, especially low forming temperatures and resistance to fatigue in bending, polypropylene and polyethylene have proven to be extremely useful in nearly all types of orthoses where high unit stresses are present. Orthoses formed from these materials not only are usually lighter in weight but present a neater appearance as well. However, no material is perfect in all respects, and because the relatively small volume needed in orthotics when compared to other fields precludes the expenditures required to develop materials specially "tailored" to orthotics, every orthotist is on the lookout constantly for new plastics as they become available commercially, and contemplates whether or not it has a place in orthotics.

Surlyn, a thermoplastic whose main use for a number of years seems to have been for golf ball covers, is the latest example of such a material. Physical char-

SOME MECHANICAL CHARACTERISTICS OF THREE THERMOPLASTIC MATERIALS

Characteristic	Units	Polypropylene	Polyethylene	Surlyn (Thermo-Vac)
Tensile Strength	PSI	4080	4200	4500
Elongation	%	390	500	380
Specific Gravity	%	.904	.940	.950

Table 1

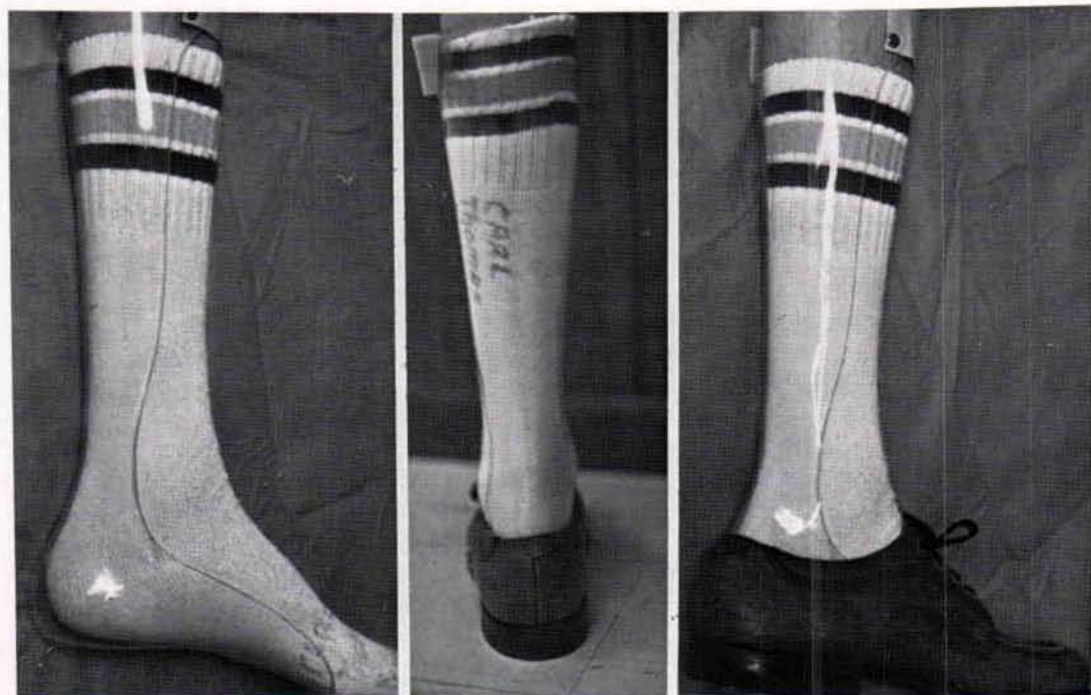


Fig. 1. Three views of a typical ankle-foot orthosis made of Surlyn.

acteristics (Table 1) of Surlyn, are quite similar to polypropylene, but, in addition, it is transparent (Figs. 1 & 2). A sheet $\frac{1}{4}$ -inch thick is almost totally transparent, and newsprint can be read through sheets of greater thickness. Surlyn is also more flexible than polypropylene.

Surlyn is the DuPont Company's registered trademark for ionomers which are resins consisting of thermoplastic polymers that are "ionically crosslinked." The ionomers are derived from ethylene/methacrylic acid copolymers and thus possess many of the characteristics found in olefin polymers such as polyethylene

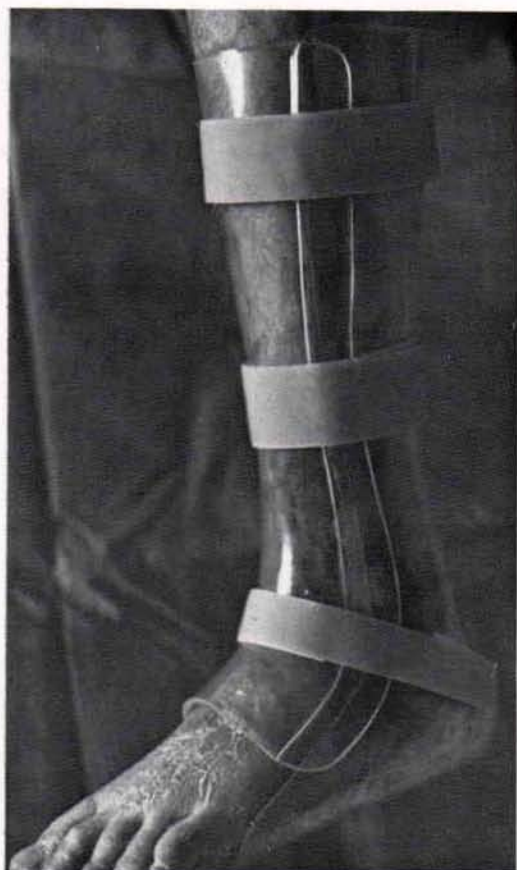


Fig. 2. An ankle-foot orthosis made of Surlyn to provide protection from impact.

and polypropylene. Surlyn resins vary in the amount of crosslinking and molecular weight and therefore the physical properties can be varied to some extent. Thermo-vac is the name given by U.S. Manufacturing Company² to the type of Surlyn most useful in orthotics and prosthetics.

Surlyn can be formed in the same manner as polypropylene, the working temperature range being from 200 to 500 degrees F. The temperature used varies according to the amount and type of forming to be done and the thickness of material being worked. The selection of time and temperature varies according to

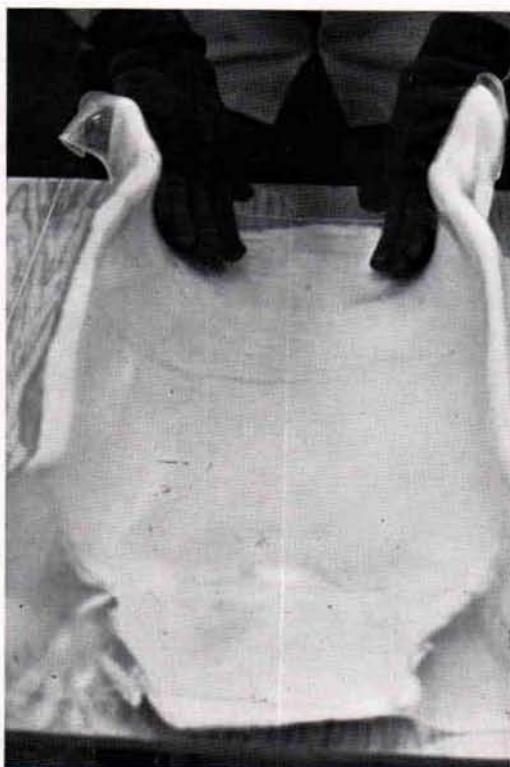


Fig. 3. Surlyn can be molded to the concave side of a body cast to eliminate need for a positive model in some instances.

the job and the technique used for forming. Hand draping of the material to the concave side of a negative spinal impression (Fig. 3) is probably best done at 250-350 degrees F. with an oven time of approximately 7 minutes. Higher temperature and time of exposure permit more penetration of the heat causing the plastic to become more fluidlike, and thus permitting more and better forming detail. The use of vacuum for forming $\frac{1}{4}$ -inch thick Surlyn contained in a frame is best done with an oven temperature of from 350 to 400 degrees F. and an exposure time of approximately 7 minutes.

Of course, the selection of thickness of

material is dependent upon the amount of immobility required and control desired in the orthosis. Obviously, the thinner the material, the less heat and time needed to bring it to a formable state. A desirable characteristic of Surlyn is that it can be formed about a wet, cold cast without producing appreciable internal stresses or expansion of the orthosis after it is removed from the model and trimmed. It can be formed directly over the model without a cloth or any other type of barrier between the material and the model. The degree of clarity to a great extent depends upon the smoothness of the surface of the model.

More than 200 spinal, upper-limb, and lower-limb orthoses, have been fabricated from Surlyn at this institution. Examples of various applications are included in the following Case Reports:

I—A patient with a peripheral neuropathy that resulted in drop foot, secondary to second-and-third-degree burns over the majority of his body, has problems with hypertrophic scarring, contractures, fragile skin, and volume changes that do not permit the use of conventional polypropylene materials. A plaster cast was taken and an AFO was fabricated from Surlyn. Total contact was provided to aid in control of the scarring. Because of the flexibility of Surlyn no pressure lines appeared along the borders of the orthosis and sufficient rigidity to maintain the foot and ankle in a neutral, 90-degree angle was achieved as a result of the shape of the cross-section. The patient can walk with a heel-toe type of gait, is free to don and doff the AFO independently, and can change shoes to meet his immediate needs.

II—A young female patient with a closed head injury resulting in hemiplegia required an orthosis to prevent



Fig. 4. The ankle-foot orthosis provided case II.

drop foot. The patient exhibited a mild degree of spasticity in the plantar flexors while the plaster impression was being made. An ankle-foot orthosis was fabricated from Surlyn that prevented the foot from dropping (Fig. 4). The patient is able to ambulate with a heel-toe gait using an orthosis that is cosmetically acceptable to her.

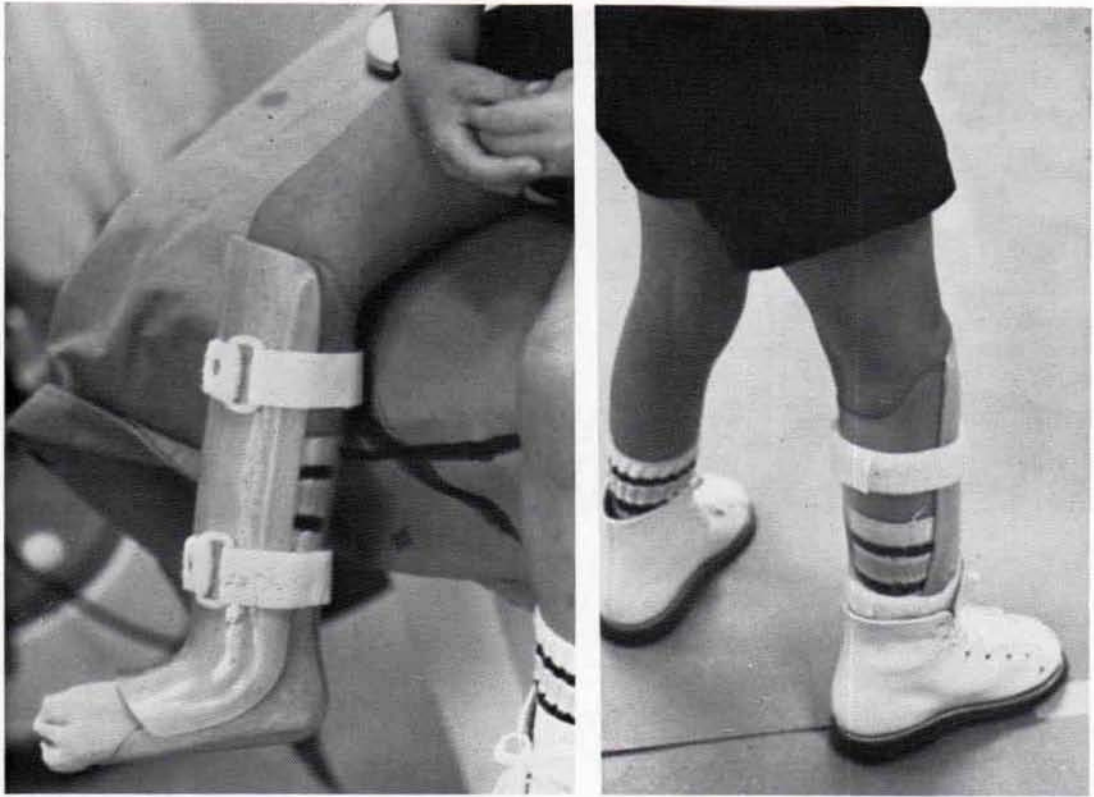

Fig. 5. The ankle-foot orthosis provided case III.

III—A young child with a psuedarthrosis of the tibia and fibula has had three recurrent fractures in the same location and had worn a conventional metal orthosis and numerous casts. A total-contact posterior-anterior shell was molded over a positive plaster model to provide complete circumferential control (Fig. 5). The orthosis, which requires no shoe modifications, was used to manage the fracture during the acute stage, and afterwards to prevent recurrence.

IV—A patient with a non-union of the ulna having approximately 4 cm of bone missing required an orthosis to stabilize

the forearm, while permitting voluntary flexion and extension about the elbow, but inhibiting supination and pronation of the forearm. An orthosis was fabricated consisting of a distal section that contains and controls the forearm about the elbow, a polycentric joint at the elbow to permit voluntary flexion and extension but inhibiting supination and pronation, and a proximal section to provide the stability needed (Fig. 6). Owing to the nature of Surlyn the orthosis can be adjusted to the patient, and therefore we do not feel that it is necessary any longer to make this type of orthosis on an individual basis. Left and right models in three different sizes are maintained for a modified off-the-shelf type fitting program.

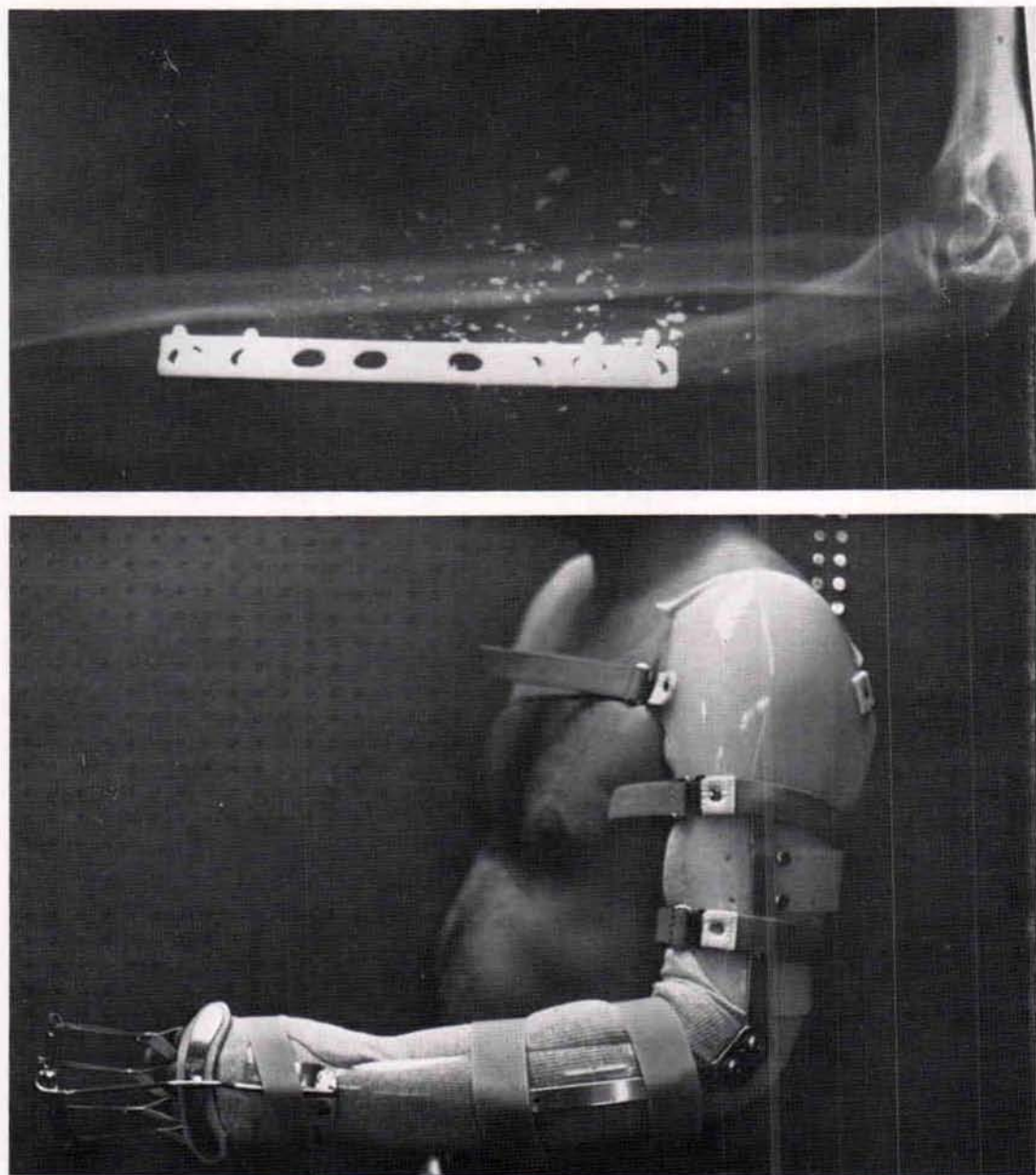


Fig. 6. Upper photo: x-ray of forearm of Case IV; lower: lateral view of the orthosis provided Case IV.

V—Patient sustained vertebral fractures of C7 and T9 and has had Harrington rod instrumentation for her thoracic fractures. A prescription was written asking for an anterior-posterior molded plastic spinal jacket with a SOMI cervical orthosis attached. The spinal jacket was

to cover the area between the sternal notch and the symphysis pubis anteriorly and between the sacrum and T3 posteriorly. A plaster-of-Paris cast of the patient was made, and the positive model was modified and corrected in the usual manner. Surlyn was vacuum formed over

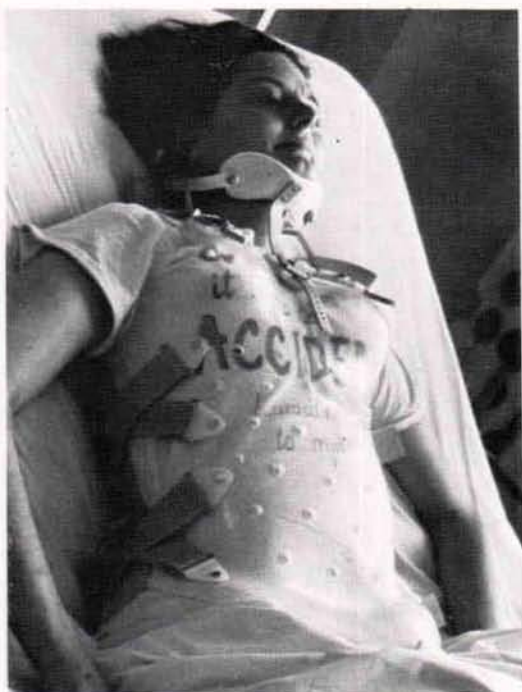


Fig. 7. The body jacket with SOMI cervical orthosis attached provided Case V.

the model in a two-stage procedure. The posterior section was formed and trimmed, replaced on the model, and the anterior section was formed. At the time of the first fitting, the SOMI orthosis was attached, final trimlines were established, and the definitive orthosis was fitted the following day (Fig. 7). This patient has no neurological deficits. She progressed from wheelchair to limited ambulation quickly and now is fully ambulatory and independent in ADL with her orthosis.

VI—Patient sustained compression fracture of T9 as a result of bone demineralization. A prescription was written for an anterior-posterior spinal jacket extending anteriorly from the sternal notch to the symphysis pubis and posteriorly from the sacrum to T3. A routine plaster-of-Paris cast was taken and normal procedures for modification of the positive were followed. Surlyn was

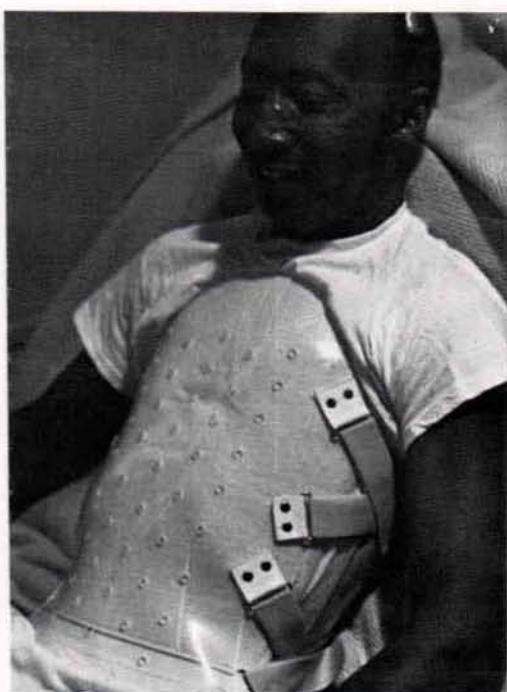


Fig. 8. Antero-lateral view of body jacket provided Case VI.

vacuum formed in two stages as in Case V (Fig. 8)

A posterior view of the spinal orthosis is shown in Figure 9. The patient is primarily a wheelchair user, and does very limited ambulation.

VII—Patient was three-months post-Harrington rod instrumentation for correction of idiopathic scoliosis. Posterior section of her orthosis was formed using the concave side of the plaster jacket which she had been wearing for three months. An anterior section of cloth was used. The orthosis (Fig. 10) provides lateral stability while permitting limited anterior flexion. It was formed and fitted in a total time of approximately three hours.

VIII—Patient sustained a navicular fracture while working as a scrub nurse on the Orthopedic Service. Prescription was written for a long opponens orthosis



Fig. 9. Postero-lateral view of body jacket provided Case VI.

with a thumb post to stabilize the navicular fracture. A plaster-of-Paris cast was taken and the positive model was modified in a routine manner. The patient was placed in a short arm navicular fracture cast and returned to the Orthotic Clinic the following day for fitting of the Surlyn orthosis. Patient continued in her duties in the OR as a circulating nurse and no time was lost from work.

Conclusions

Experience at our center which has been limited to applications in orthotics, indicates that Surlyn is the material of choice where more flexibility is desirable than that provided by polypropylene. Use

of Surlyn in body jackets and upper-limb orthoses seems to be especially desirable. Fewer applications seem to be indicated in lower-limb orthoses where high unit stresses are expected.

Other centers are encouraged to experiment with Surlyn in both orthotics and prosthetics.

Acknowledgement

We wish to express our appreciation for the assistance provided us by J. Morgan Greene and George Irons of the United State Manufacturing Company² in carrying out this study.

¹Division of Orthopedics, University of Texas Health Science Center at Dallas, 5323 Harry Hines Boulevard, Dallas, Texas 75235.

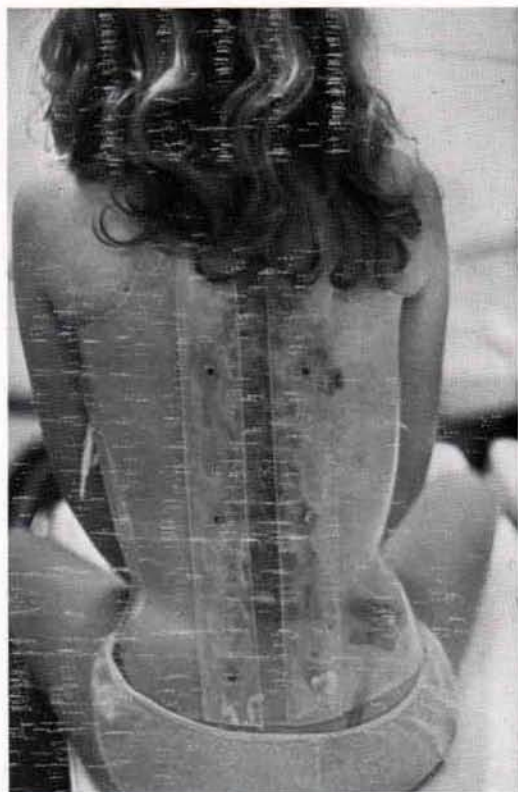

Fig. 10. Posterior view of body jacket provided Case VII.

References

- (1) Artamonov, Alex, *Vacuum-Forming Techniques and Materials in Prosthetics and Orthotics*, Inter-Clin. Inform. Bull., 11:10;9-18, July 1972.
- (2) Artamonov, Alex, *Vacuum-Forming of Sheet Plastics*, ISPO Bulletin, No. 4, October 1972.
- (3) Aylesworth, R. Deane, ed., *Manual of Upper Extremity Prosthetics*, Artificial Limbs Project, University of California, Los Angeles, 1952.
- (4) Committee on Prosthetics Research and Development, *Workshop on Vacuum-Forming Equipment, A Report of a Meeting*, National Academy of Sciences, June 1973.
- (5) Mooney, Vert, and Roy Snelson, *Fabrication and Application of Transparent Polycarbonate Sockets*, Orth. & Pros., 26:1:1-13, March 1972.
- (6) Stills, Melvin, *Thermoformed Ankle-Foot Orthoses*, Orthotics and Prosthetics, Vol. 29, No. 4, December 1975.
- (7) Street, Dana M., *Plastic Braces*, Orthopedic Appliances Atlas, Vol. 1, Edwards Brothers, Ann Arbor, Mich. 1952.
- (8) Wilson, A. Bennett, Jr., David Condie, Charles Pritham, and Melvin Stills, *Lower-Limb Orthotics, A Manual*, Rehabilitation Engineering Center, Moss Rehabilitation Hospital, Philadelphia, 1977.
- (9) Yates, Gordon, *A Method for the Provision of Lightweight Aesthetic Orthopaedic Appliances*, Orthopaedics: Oxford, 1:2:153-162, 1968.

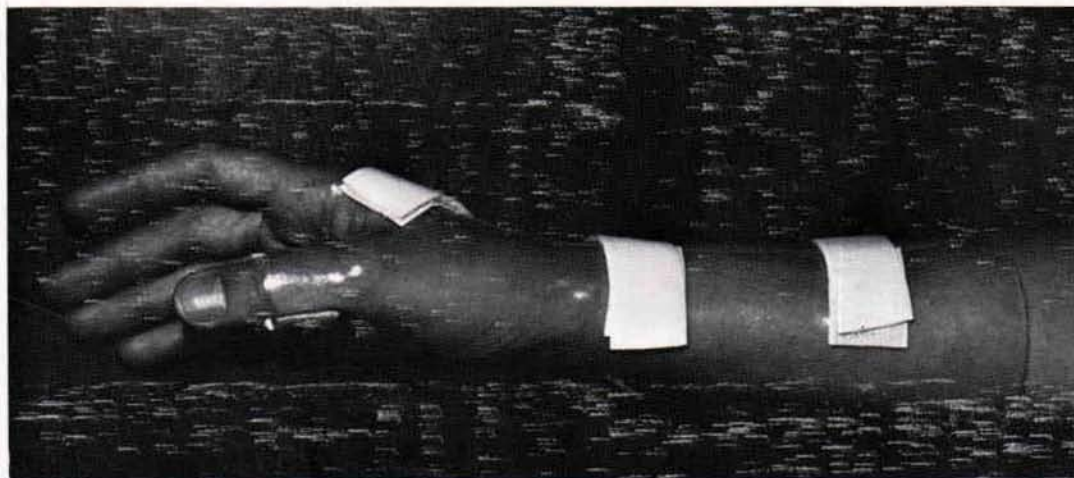


Fig. 11. Medial view of orthosis provided Case VIII.