

# Role of Cephalo Cervico Thoracic Dynamic Splint in Management of Congenital Torticollis

Col. H.C. Joshi  
Lt. Col. B.P. Mathur  
Lt. Col. H.S. Oberoi

## INTRODUCTION

Congenital torticollis, an entity which, though perhaps occurs due to birth injury, manifests itself at five to six years of age. In a large number of cases, it is missed at birth, and is recognized only when deformity has set in.

The recognition of the condition at an early stage—before gross facial and neck deformities have set in—and its adequate treatment, are therefore of paramount importance.

Immobilization of the head and neck in a corrected or overcorrected position is a must during post-operative management of torticollis patients. This has been achieved by using a bulky and uncomfortable orthosis currently in use. However, these devices are static and therefore maintain the position of head and neck at the same place during the entire period of immobilization, unless the entire orthosis is changed again at great inconvenience and cost to the patient.

It was therefore decided to make an orthosis that would be light, hygienic, less cumbersome to wear, and dynamic in nature, so that it not only maintained the head and neck in its corrected position, but also helps in exerting corrective forces to achieve further correction/overcorrection.

## MATERIAL AND METHOD

Seventeen cases of congenital torticollis were treated at the Armed Forces Medical College, Artificial Limb Centre Pune, and a large base hospital, between 1970 and 1980.

History of involvement of other members of the family and congenital bias were investigated. Details were taken of the history of pregnancy. Problems arising in the labor, such as forceps delivery and prolonged or difficult labor, were also noted.

All cases were thoroughly investigated and, where necessary, x-rays of cervical spine and thoracic outlet were taken to exclude any abnormalities in this region. Every case above three years of age was referred to an ophthalmologist to exclude any primary or secondary ocular problems in these cases.

We felt that to get the best results, motivation and close co-operation of the patients in the post-operative period were very essential. Thus, all patients and their parents were fully apprised of the importance of the post-operative regimen.

## TORTICOLLIS SPLINT

The Torticollis corrective orthosis designed by us consists of cephalic and

shoulder girdle bands, a harness, and straps for providing dynamic corrective forces (Figures 1, 2, & 3).

Cephalic and shoulder bands are made of polyethylene. These bands are made by accurately forming them over the positive molds obtained from the negative molds of the regions. This provides an intimate fit of these bands around the head and over the opposite shoulder.

The cephalic band is circular in shape and open anteriorly. It is fastened to the head with a Velcro® strap anteriorly.

The shoulder band is horse-shoe shaped and also conforms to the contours and depression over its upper, anterior, and posterior aspect. It is fastened into place by a Velcro® strap under the axilla.

In order to prevent the displacement of cephalic and shoulder polyethylene bands from their original position when the corrective forces are in operation, a harness system is essential. The shoulder band is retained in its place by a figure eight harness mechanism, whereas the cephalic

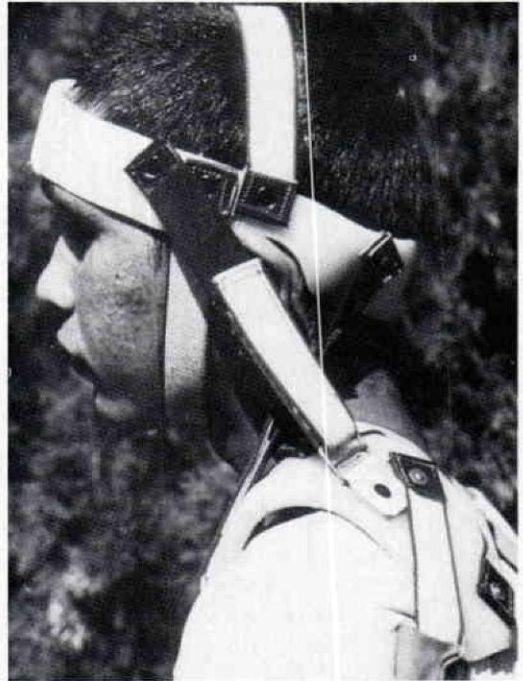

Figure 1. Lateral view of the orthosis.

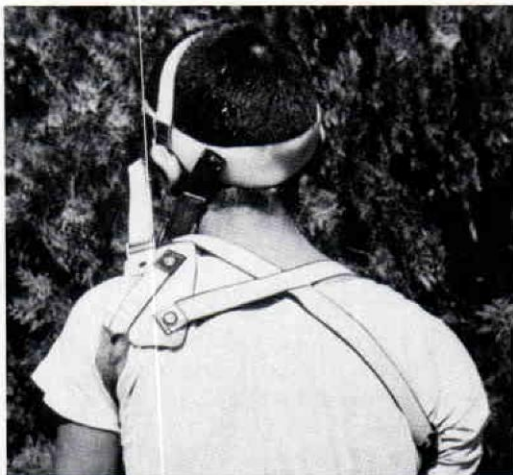


Figure 2. Posterior view.




Figure 3. Anterior view.

band is retained in its place by chin and overhead straps.

The dynamic force-exerting bands are attached to the shoulder band and the cephalic band in a criss-cross fashion. The upper fixed attachment points of these straps are located anteriorly and posteriorly to the sagittal plane. The lower free

ends of these straps are attached to the buckles fixed over the anterior and posterior aspect of the shoulder band.

These straps are made of a tough elastic material and by exerting appropriate pull on them, the head, neck, and chin can be maintained in a corrected position post-operatively. By increasing tension in the

bands gradually, mild deformities can be corrected without any operation, and undercorrected deformities can be fully corrected in due course.

## OBSERVATIONS

In this series we had three females and fourteen males. Except in two cases, we did not find any unusual problems associated with the pregnancy or delivery. Four cases reported to us within one year, and an equal number were seen within the first five years. We had six cases between five and ten years of age, and three cases beyond ten years of age.

We found pain and tenderness only in the sternomastoid in three cases. There was induration and localized swelling in the sternomastoid in six cases, and a short and tense sternomastoid without any swelling in the other eight cases.

We divided these cases according to the severity of deformity:

- *Stage I*—Minimal tilting of the head with or without tenderness of muscle.
- *Stage II*—Moderate tilting of the head.
- *Stage III*—Severe tilting of the head with secondary changes in face and skull.

We had six cases with Stage I, eight cases with Stage II, and three cases with Stage III torticollis in this series.

## TREATMENT

We received four infants in the first few months after birth. All of them had marked tenderness in the lower part of the sternomastoid. All these cases were treated conservatively by manipulation. The correct method of manipulation was taught to the parents and they were advised to carry out the procedure at their home. They were reviewed at monthly intervals. Parents of three other cases, two of Stage I and one of Stage II, refused operation and were thus treated by conservative treatment and splints.

An operation was done in ten cases. Simple division of the sternomastoid at its lower end was done in six cases. More extensive excision of the lower part of the

sternomastoid and division of the fascia and strap muscle and the other tissues holding correction was done in four cases. Postoperative healing was uneventful in all cases.

## POSTOPERATIVE MANAGEMENT

Every attempt was made to keep the corrected position of head and neck by cast immobilization or by dynamic orthosis. Our first four cases were treated with casts, but later we treated all our postoperative cases with the dynamic orthosis.

## RESULTS

Seven patients were treated by manipulation and dynamic orthoses. Four patients with Stage I deformity had good results. In two patients with Stage II deformity and one with Stage I deformity, results were not satisfactory. Ten patients were treated by operation and maintenance of post-operative corrective position by cast or orthosis. Out of six cases of Stage II deformity, the results were good in four cases, satisfactory in one, and poor in one. There were three cases of Stage III deformity, out of which results were satisfactory in one case and poor in the remainder.

## DISCUSSION

Many factors have been blamed for the causation of congenital torticollis. This series is too small to throw any further light on this subject.

The results of treatment of these cases depend not only on the surgical correction, but also on the time when the treatment is started (Coventry, 1959).<sup>4</sup> If the treatment is started in infancy, many of these could be controlled by manipulation and later by giving them dynamic orthoses. We achieved good results in such cases by this procedure in 62 percent of the cases. But the biggest problem we find here is that a considerable percentage of cases are lost in follow-up, and we do not know actually

what the final results are when the children reach seven or eight years of age.

The operative procedure for correction of torticollis is simple, but may need extensive division of fascia and contracted muscles or any tissue which prevents the correction. This has to be reviewed meticulously at the time of operation, as was suggested by Brown (1950).<sup>2</sup>

We agree with Armstrong (1965)<sup>1</sup> that of equal importance is the maintenance of corrected position in the postoperative period. We maintained the corrected position for a prolonged period of four to six months. Initially we maintained this position by case immobilization, but this is cumbersome, heavy, and becomes intolerable in summer. Two of our patients removed it by themselves and reported with recurrence of deformity.

After many experimentations and considerable efforts, we have tried to find an ideal orthosis for this condition. The Buckminster-Brown type of orthosis used in the past was bulky and difficult to fit. Even the orthosis by Lango (1977)<sup>5</sup> is static.

We have now devised a cephalo cervico thoracic dynamic orthosis to be given to these patients in their postoperative phase and in early Stage I cases and all those who refused operation. It is light and comfortable. It is readjusted from time to time and

can be used for as long as required. It is opened two or three times a day to give physiotherapy and manipulation.

We used this orthosis in ten cases. Six were given this orthosis after operation and four were given to those who were early Stage I or who had refused operation. The results after its use were consistently good. The further management of cases in their post-operative period became comfortable for the patients and easy for the treating surgeon. The orthosis, described here, is mechanically sound and contains dynamic corrective forces ingrained in it. It has been very well accepted by all of our patients.

#### REFERENCES

- <sup>1</sup>Armstrong, Dali, Pickrell (1965), "Torticollis, An Analysis of 271 cases," *Plastic Reconstruction Surgery*, 35:14.
- <sup>2</sup>Brown, J.B. & McDowell, R. (1950), "Wry neck facial distortion prevented by resection of fibrous sternomastoid," *Annals of Surgery*, 131:721.
- <sup>3</sup>Chandler, F.A. (1948), "Muscular Torticollis," *Journal of Bone & Joint Surgery*, 30-A:566.
- <sup>4</sup>Coventry, M.D. and Harris, L. (1959), "Congenital muscular torticollis in infancy. Some observations regarding treatment," *Journal of Bone & Joint Surgery*, 41-A:815.
- <sup>5</sup>Lango, S., and Schwentker, E.P. (1977), "Orthotic Treatment of Muscular Torticollis," *Inter Clinic Information Bulletin*, XVI-11 & 12, 13.

#### AUTHORS

- Colonel Joshi is Professor of Surgery, Armed Forces Medical College, Pune-40, India.  
 Lt. Col. Oberoi is a Reader in Surgery at the College.  
 Lt. Col. Mathur is Surgeon and Deputy Commandant of the Artificial Limb Centre at Pune.