

Case note—fitting of an artificial limb after 43 years

G. J. A. SIRIWARDENA

Artificial Limb and Appliance Centre, Birmingham.

The patient, a 48 year old Indian with a right above knee amputation, first attended Wolverhampton Artificial Limb and Appliance Centre in 1978. As a 5 year old child in India he had fallen from a camel, sustaining a compound fracture of the tibia and fibula which had become severely infected necessitating amputation. Within a few weeks the amputation was healed and the first prosthesis he tried out was a bamboo pole with a sling to support the stump as shown in the accompanying photograph (Fig. 1, left). This prosthesis was designed and built by his father. He grew up using the bamboo pole which gave him excellent mobility whilst working as a farmer and shopkeeper in his village.

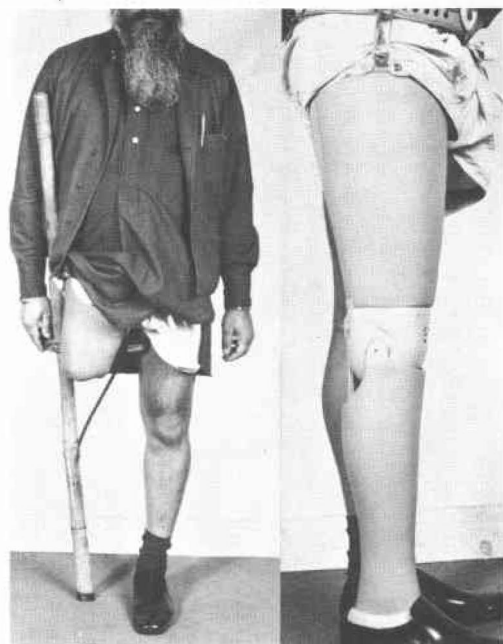


Fig. 1 Left, bamboo pole with supporting sling. Right, the patient fitted with a modular assembly above-knee prosthesis.

All correspondence to be addressed to Mr. G. J. A. Siriwardena, Hon. Consultant in Prosthetics and Orthotics, Artificial Limb and Appliance Centre, Oak Tree Lane, Selly Oak, Birmingham B29 6JA.

He came to England in April 1978 to join relatives already here. In May he suffered a simple influenza-like illness for which he was seen by his doctor, who suggested to him in passing that he could have a proper artificial limb. He attended Wolverhampton ALAC on 7th September 1978 when he was observed to be extremely mobile on his bamboo pole. He stated that he could walk as far as any normal person; this statement was found to be true.

On examination he had a good right above-knee stump of 13 cm, as measured from the tip of the greater trochanter, with a full range of movement of that hip joint. A modular assembly prosthesis was ordered on the same day and this was delivered to him on 12th December 1978 (Fig. 1, right).

Immediately after receiving the artificial limb he walked extremely well despite the fact that the prosthesis incorporated a "free" (i.e. not locked) stabilised knee unit and within a few months he was able to walk without the use of any other aid.

He was seen again on 25th January, 1979 and he was very pleased with his leg. He could walk well and had no problems; he had by this time discarded his bamboo pole.

Acknowledgements

I wish to thank Mr. K. B. Allcock LBIST, prosthetist, who attended the case, Dr. Arora, General Practitioner, Wolverhampton, and Mr. Alan English FRCS, Principal Medical Officer, Artificial Limb and Appliance Service of DHSS, for giving me permission to publish this case and also advice regarding the writing of this article.

FURTHER READING

Ross, W. F. (1963). Oji River Settlement. *Leprosy Rev.* 34, 151.

SIRIWARDENA, G. J. A. (1977). Fitting of an artificial limb after 56 years. *Injury* 6, 343.